

CASE REPORT

Accelerated Extraction Treatment with Invisalign

KENJI OJIMA, DDS
CHISATO DAN, DDS
RIKI NISHIYAMA, DDS
SUMIMASA OHTSUKA, DDS, PHD
WERNER SCHUPP, DDS

We have seen a rising demand in recent years, especially from adults, for inconspicuous and natural-feeling orthodontic appliances. When the Invisalign* system was introduced, it had limitations such as the inability to control root movement and to move larger teeth over substantial distances.¹⁻³ Advances in the quality of aligner materials and attachments and the introduction of a new force system, however, have expanded the range of treatment possibilities from mild crowding to more difficult extraction cases.⁴⁻¹⁴

Even with aligner therapy, one of the greatest sources of dissatisfaction among adult patients remains the length of treatment. This report describes a patient with severe anterior crowding who was treated with Invisalign appliances after the extraction of both upper canines and lower first premolars, using a microvibration device to accelerate tooth movement.

Diagnosis and Treatment Plan

This 26-year-old female

expressed a desire to correct her maxillary anterior crowding and improve the esthetic appearance of her smile. The patient's facial profile was straight, but both lips were slightly recessive with regard to the E-line (Fig. 1). Intraoral examination showed a Class II molar relationship with a 3mm overjet, a 1mm overbite, and coincident midlines. The arch-length discrepancy was 13mm in the maxilla and 10mm in the mandible. We noted infralabioversion of both upper canines

*Registered trademark of Align Technology, Inc., San Jose, CA; www.align.com.



Dr. Ojima



Dr. Dan



Dr. Nishiyama



Dr. Ohtsuka



Dr. Schupp

Drs. Ojima, Dan, Nishiyama, and Ohtsuka are in the private practice of orthodontics in Tokyo, Japan. Dr. Schupp is in the private practice of orthodontics in Cologne, Germany, and is a Visiting Professor, Department of Stomatology, Capital University, Beijing, China. Contact Dr. Ojima at Hongo Sakura Orthodontics, Kataoka Building 2F, 2-39-5 Hongo, Bunkyo-ku, Tokyo 113-0033, Japan; e-mail: kenjiojima@i.softbank.jp.

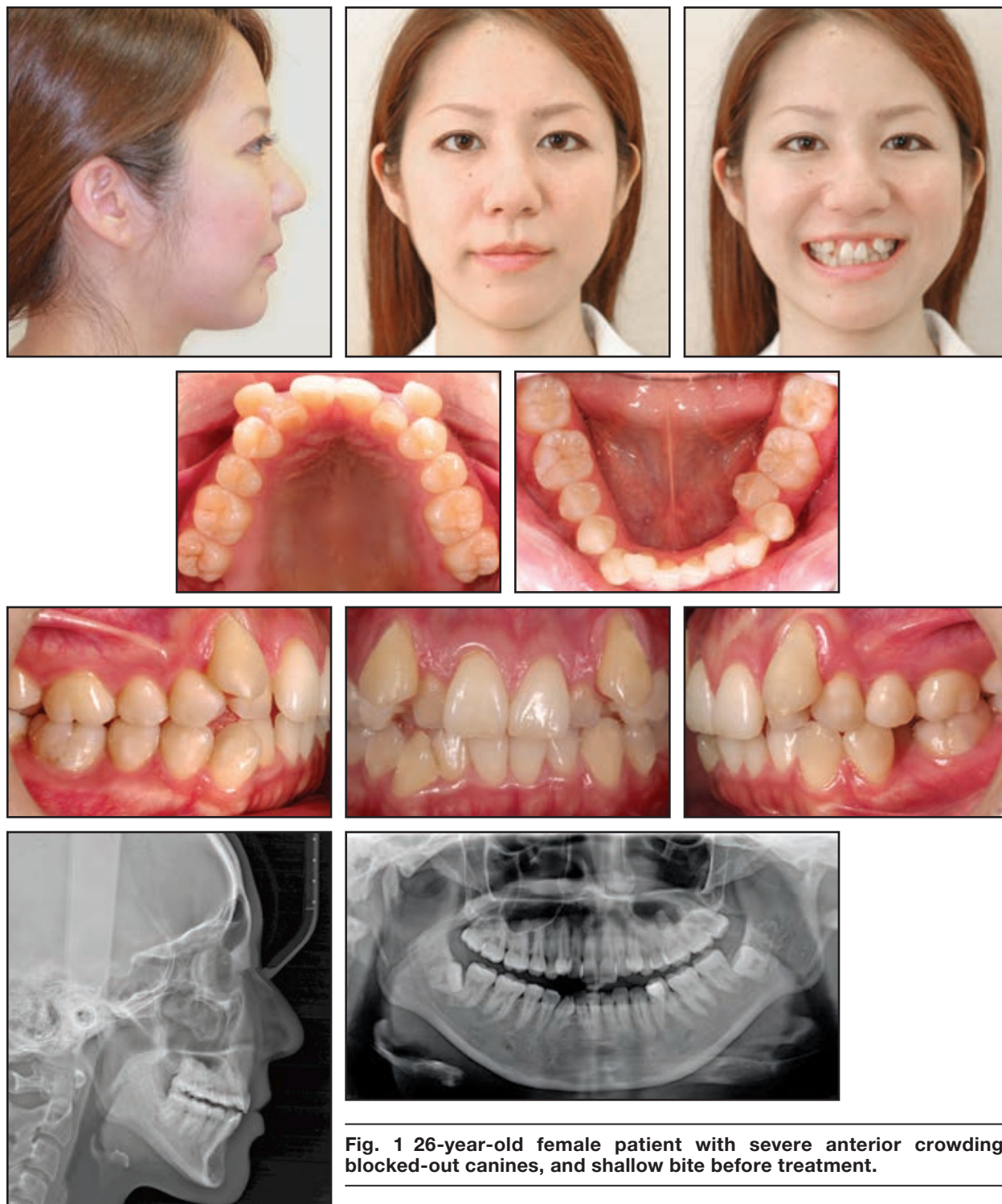

Fig. 1 26-year-old female patient with severe anterior crowding, blocked-out canines, and shallow bite before treatment.

TABLE 1
CEPHALOMETRIC ANALYSIS

	Norm	Initial	Final
SNA	81.5 ± 3.5°	81.0°	80.5°
SNB	77.6 ± 3.7°	74.5°	74.0°
ANB	3.7 ± 1.9°	6.5°	6.5°
U1-NA	22.1 ± 7.0°	13.0°	13.0°
L1-NB	29.5 ± 5.5°	31.0°	31.5°
Interincisal angle	124.7 ± 8.8°	132.0°	130.0°
Occlusal plane to SN	15.1 ± 4.8°	22.0°	21.5°
Go-Gn to SN	30.4 ± 6.3°	42.0°	41.5°
FMA	27.3 ± 3.1°	34.5°	35.0°
IMPA	95.5 ± 3.1°	92.0°	89.5°
FMIA	57.2 ± 3.9°	53.5°	55.5°
Overbite		1.0mm	2.0mm
Overjet		3.0mm	2.0mm
Arch-length discrepancy (upper)		-13.0mm	
Cephalometric discrepancy (upper)		-4.8mm	
Total discrepancy (upper)		-17.8mm	
Arch-length discrepancy (lower)		-10.0mm	
Cephalometric discrepancy (lower)		-4.8mm	
Total discrepancy (lower)		-14.8mm	

and a marked linguoversion of the lower left second premolar.

Cephalometric analysis indicated a skeletal Class II relationship with a steep mandibular plane angle (Table 1). The upper central incisors were slightly inclined lingually, and the lower central incisors labially. The panoramic x-ray confirmed a lateral gap in the mandibular head, but this did not impede mandibular function. The periodontal tissue around the upper canines evidenced significant regression; while there was no tooth mobili-

ty, the maximum pocket depth was 11mm.

Based on these observations, we diagnosed the case as a skeletal Class II with infralabioversion of the maxillary canines and a steep mandibular plane angle. The treatment plan called for retraction of both upper and lower incisors—17.8mm in the maxilla and 14.8mm in the mandible—after extraction of the four first premolars.¹⁵⁻²⁰ Because of the poor condition of the periodontal tissues around the upper canines, however, the patient would have required either long-term periodontal treatment or periodontal surgery. Therefore,

we agreed to extract both upper canines instead of the upper first premolars. The patient also expressed concern about the esthetic appearance of fixed orthodontic appliances over a potentially long period, so we decided to implement the Invisalign system in conjunction with AcceleDent** to speed up treatment.

We fabricated plaster setup models to analyze the location, angle, and need for recontouring of the first premolars in relation to the final occlusion (Fig. 2). Adequate incisor retraction in this Class II malocclusion required a 2mm distal movement of the upper first molars and a

**Registered trademark of OrthoAccel Technologies, Inc., Bellaire, TX; www.aceledent.com.

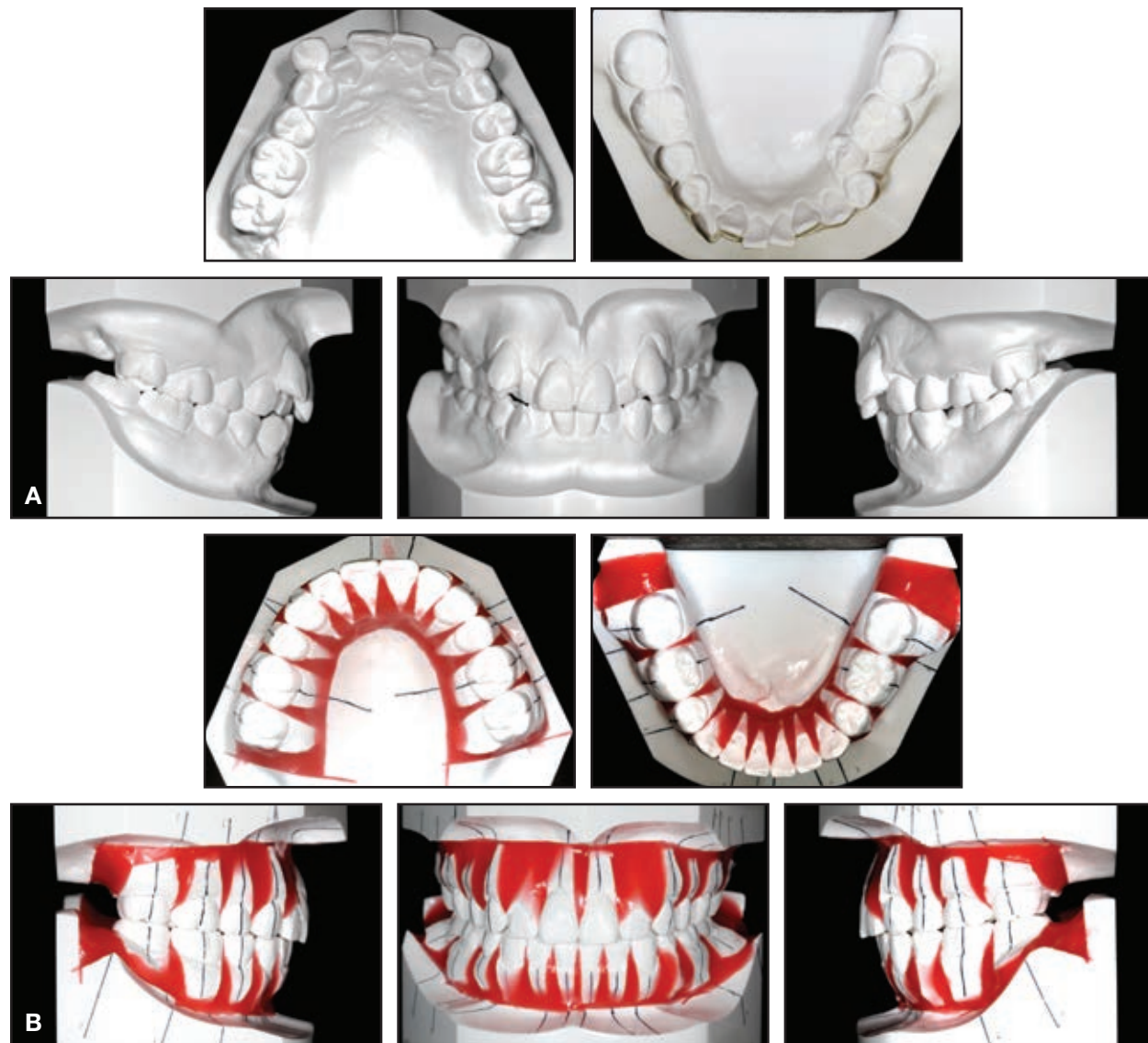


Fig. 2 A. Pretreatment plaster models. B. Setup of final occlusion.

2mm mesial movement of the lower first molars. Because there was insufficient space to move the maxillary anterior teeth by molar distalization alone, even after the extractions, we planned an overexpansion of the dental arches. Using the setup models

as a guide, we simulated tooth movements on the ClinCheck* software (Fig. 3). We then estimated the amount of expansion we would need in each arch (Fig. 4) and planned the positions and shapes of the required attachments (Fig. 5).

Treatment Progress

All four third molars were removed before treatment. After extraction of the upper canines and lower first premolars, align-

*Registered trademark of Align Technology, Inc., San Jose, CA; www.align.com.

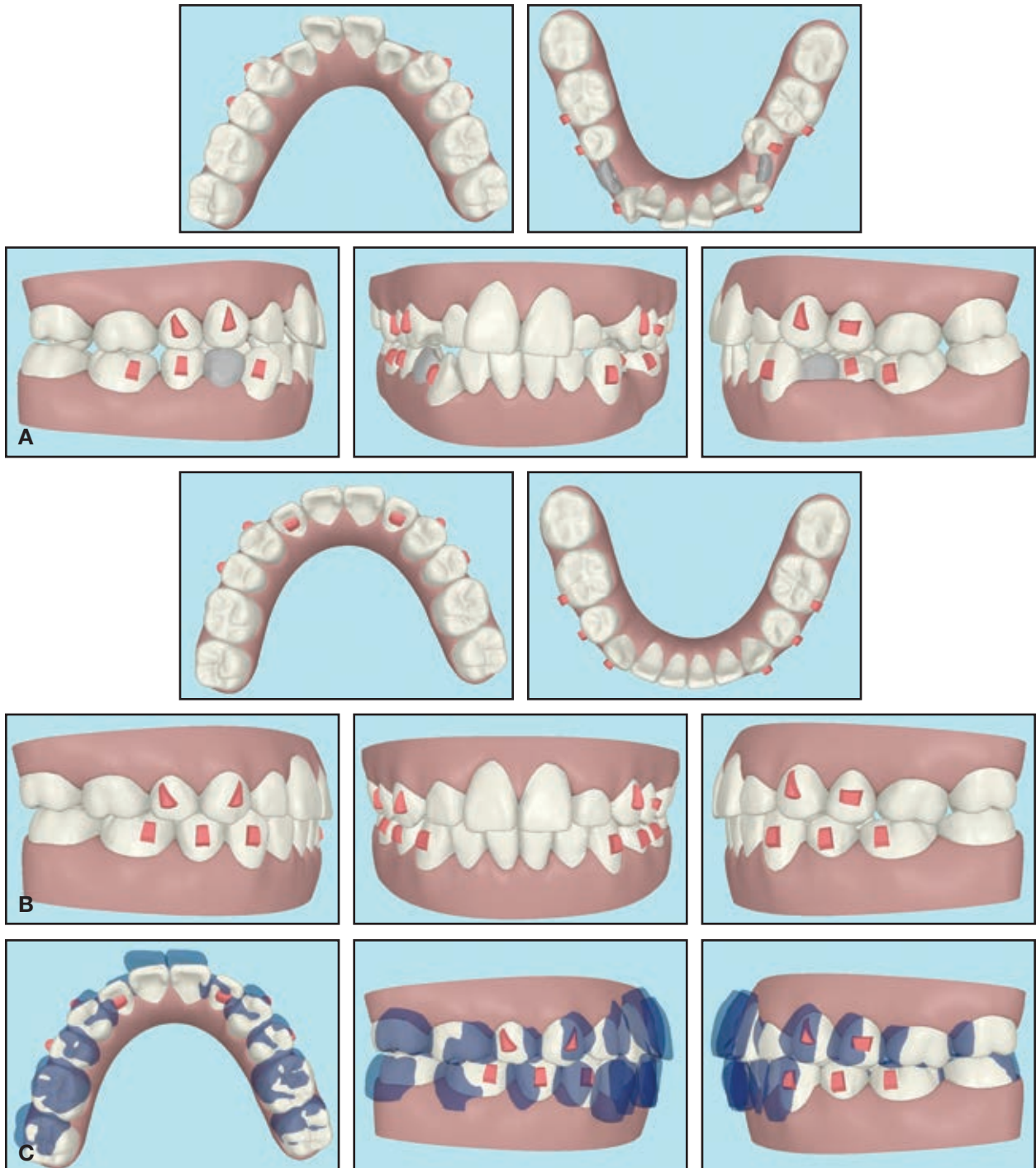


Fig. 3 A. Pretreatment ClinCheck setup, with upper canines already removed and lower first premolars shaded for removal. B. ClinCheck prediction of final occlusion. C. Superimposition of pretreatment and projected post-treatment ClinCheck images.

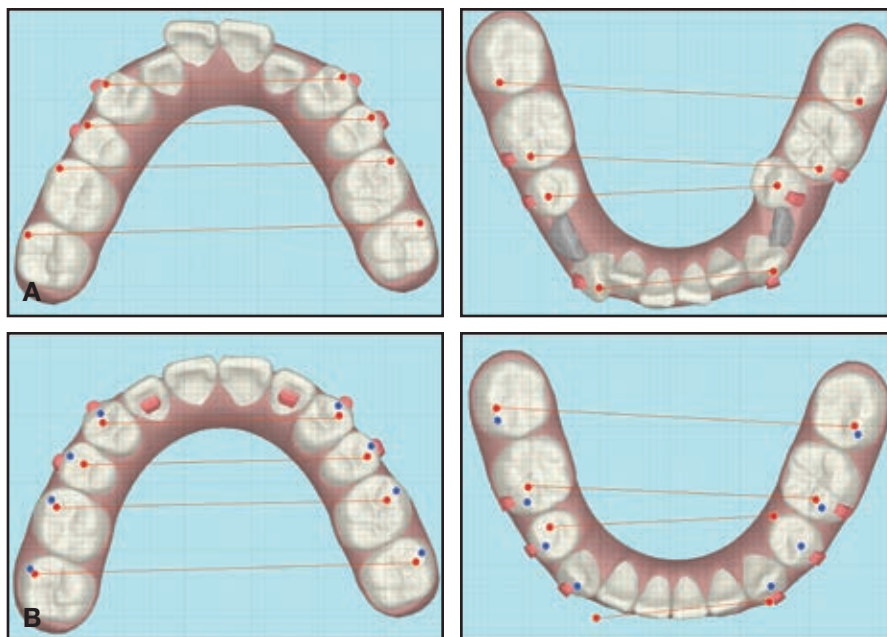
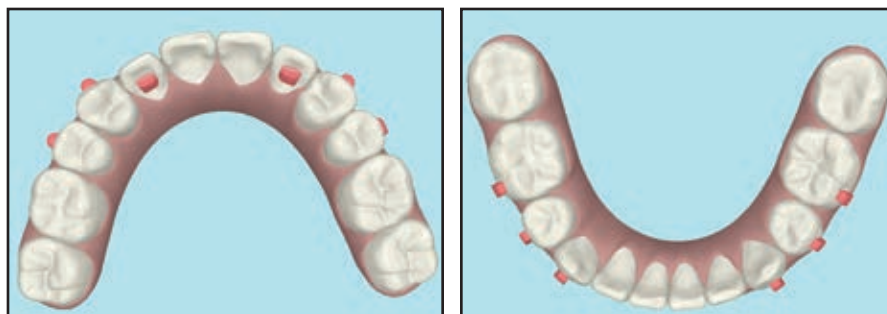

Fig. 4 Pretreatment intercuspal widths measured on pretreatment ClinCheck images (A) and superimposed on post-treatment images (B); blue dots indicate cusp positions after arch expansion.



Upper Arch	17	16	15	14	13	12	11	21	22	23	24	25	26	27
Attachment Type	-	-	O	O	-	R	-	-	R	-	O	R	-	-
Attachment Type	-	V	V	-	V	-	-	-	-	V	-	V	V	-
Lower Arch	47	46	45	44	43	42	41	31	32	33	34	35	36	37

Fig. 5 Planned attachment locations and types (O = optimized; V = vertical rectangular; R = horizontal rectangular).

er treatment was initiated. We used all the maxillary teeth from first molar to first molar as anchorage for distal movement of the second molars (Fig. 6A). In the mandible, we used all the teeth excluding the canines and second premolars as anchorage for mesial movement of the canines. Since the root of the lower right canine was angled outward, we moved the tooth simply by tipping; the lower left canine was moved bodily along with its root. Distal movement of the upper second molars was completed in 12 weeks, and distal movement of the upper first molars in an additional two weeks (Fig. 6B). Lower extraction-space closure continued during this period with mesialization of the lower first molars (Fig. 6C).

After 33 weeks of treatment, distal movement of the upper premolars had been completed, with the incisors in an edge-to-edge relationship (Fig. 6D). At this point, we recalculated the retraction space for the maxillary incisors by means of a panoramic x-ray. Since the mandibular extraction spaces were closed, we could use all the teeth from second premolar to second premolar, including the canines, as anchorage for mesial movement of the lower first molars.

The aligner margins were trimmed about 3mm to accommodate direct-bonded hooks on the upper first premolars (Fig. 6E). Lingual buttons were bonded to the distobuccal edges of the lower first molars, and Class II elastics (16oz medium) were prescribed to be worn 20 hours

per day. To prevent mesial tipping of the lower first molars, we added vertical rectangular attachments to their mesiobuccal edges. Instead of making precision cuts in the trays, we attached the buttons and hooks directly to the teeth to maintain proper aligner fit.

Improvement was seen in the anteroposterior relationship after use of the Class II elastics, and a Class I relationship was established in the buccal segments. The next phase involved retraction of the upper anterior teeth. Because of the tendency for aligner fit over the lateral incisors to worsen over time, we added attachments to the lingual surfaces of these teeth. After 10 months of treatment, the first ClinCheck phase was finished (Fig. 6F). Distal movement of the upper first molars was complete, with space visible at the mesial edge of the upper left first molar. Movement of the lower second premolars and canines had closed all mandibular spaces.

The shapes and positions of the attachments were modified for the refinement phase, based not only on the crown positions, but on the root positions as well. After 13 months of treatment, the aligner compatibility and the crown and root positions were all comparable to the computer-simulated predictions (Fig. 6G).

In the final stages of refinement, we confirmed occlusal contact of all upper and lower molars and a one-to-two-tooth occlusal relationship in the buccal segments (Fig. 6H). The overbite and overjet were each 1mm.

After a total 18 months of treatment, all buttons, hooks, and attachments were removed. The patient was instructed to wear Class II elastics at night for an additional four months.

Treatment Results

The patient's chief complaint—the infralabioversion of the canines—was resolved, and the improvement in gingival esthetics yielded a pleasant smile (Fig. 7A). The lips were positioned appropriately in relation to the E-line; thanks to the retraction of the maxillary incisors, the upper lip was particularly natural and relaxed. A Class I molar relationship with symmetrical arches was achieved, and all spaces were closed. The physiologically correct overbite and overjet maintained the coincidence of the dental and facial midlines.

Post-treatment protrusive and lateral movements of the mandible were smooth and linear. The patient was probably biting with considerable force in centric occlusion due to nervousness during the initial examination, resulting in a slight opening of the molar contacts that we did not recognize as initial occlusal sliding or similar instability of the occlusion. In later images, the patient was more relaxed.

Panoramic x-rays confirmed that there was no change in the level of the alveolar bone, which remained in stable and healthy condition. Although there were no signs of root resorption, there was some lack of

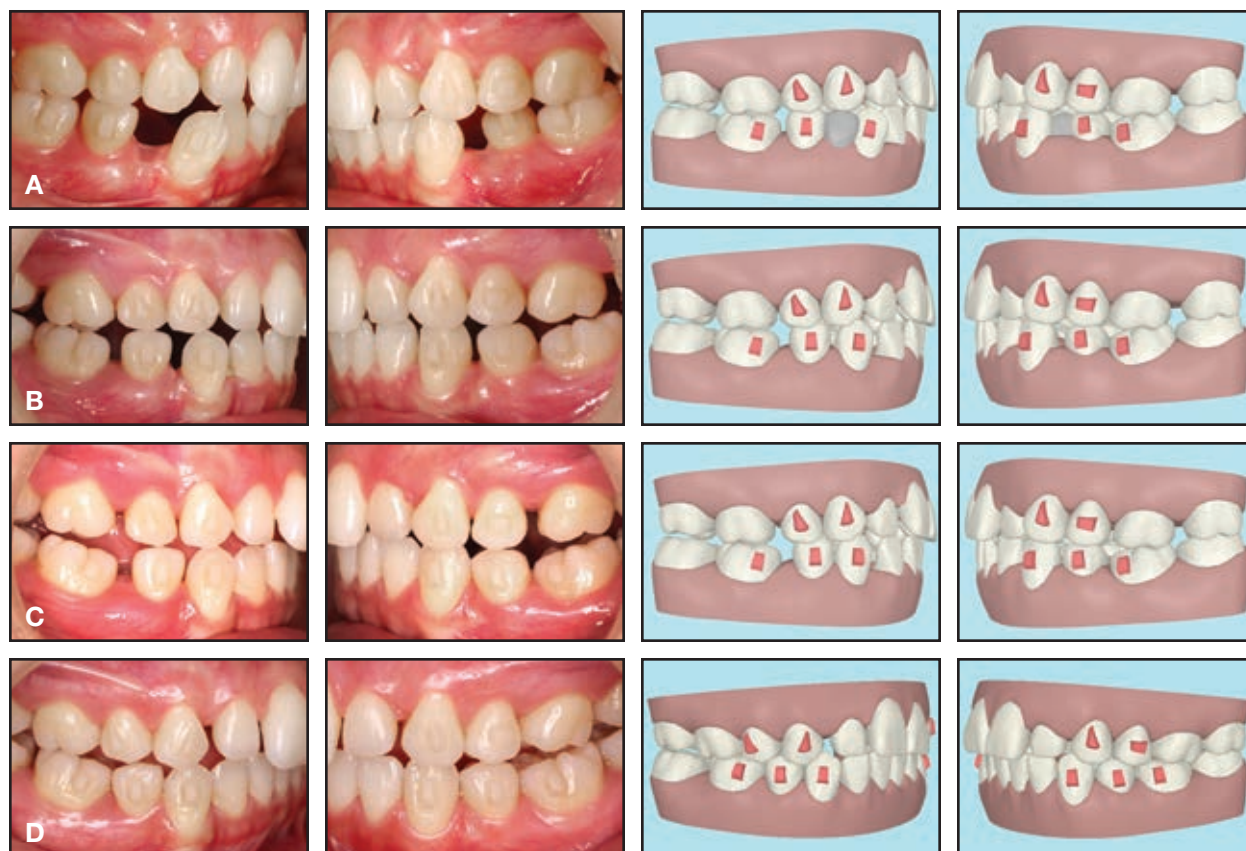

Fig. 6 Progress of treatment and corresponding ClinCheck images. **A.** After one month of treatment (aligner stage 10). **B.** After three months of treatment (aligner stage 18). **C.** After five months of treatment (aligner stage 30). **D.** After eight months of treatment (aligner stage 48) (continued on next page).

parallelism, especially of the lower right lateral incisor.

Cephalometric analysis indicated that the mandibular plane angle was slightly reduced (Table 1). Superimpositions showed that while the upper and lower incisors were retruded, their axes were upright and closer to the norm (Fig. 7B).

Discussion

Aligners appeal to adults because of their esthetic appear-

ance and their ability to produce gradual tooth movements with light forces spread out over time. Previous reports have focused on cases without extractions or with only partial extractions, perhaps due more to the difficulty of closing spaces without crown tipping than to the difficulty of moving teeth. When extraction spaces are closed with aligners, a bowing effect is often caused by sagging of the plastic around the extraction sites. This effect can be prevented by using Class II

elastics to enhance intermaxillary anchorage (Fig. 8). If an elastic is attached directly to an aligner, however, the plastic will separate from the teeth, making it more difficult to maintain control over mesial and distal tooth movements. In the case shown here, we attached direct-bonded hooks to the first premolars in the canine positions, so that the teeth could rotate both mesially and distally within the aligners (Fig. 6E-G). At the same time, we added vertical rectangular at-

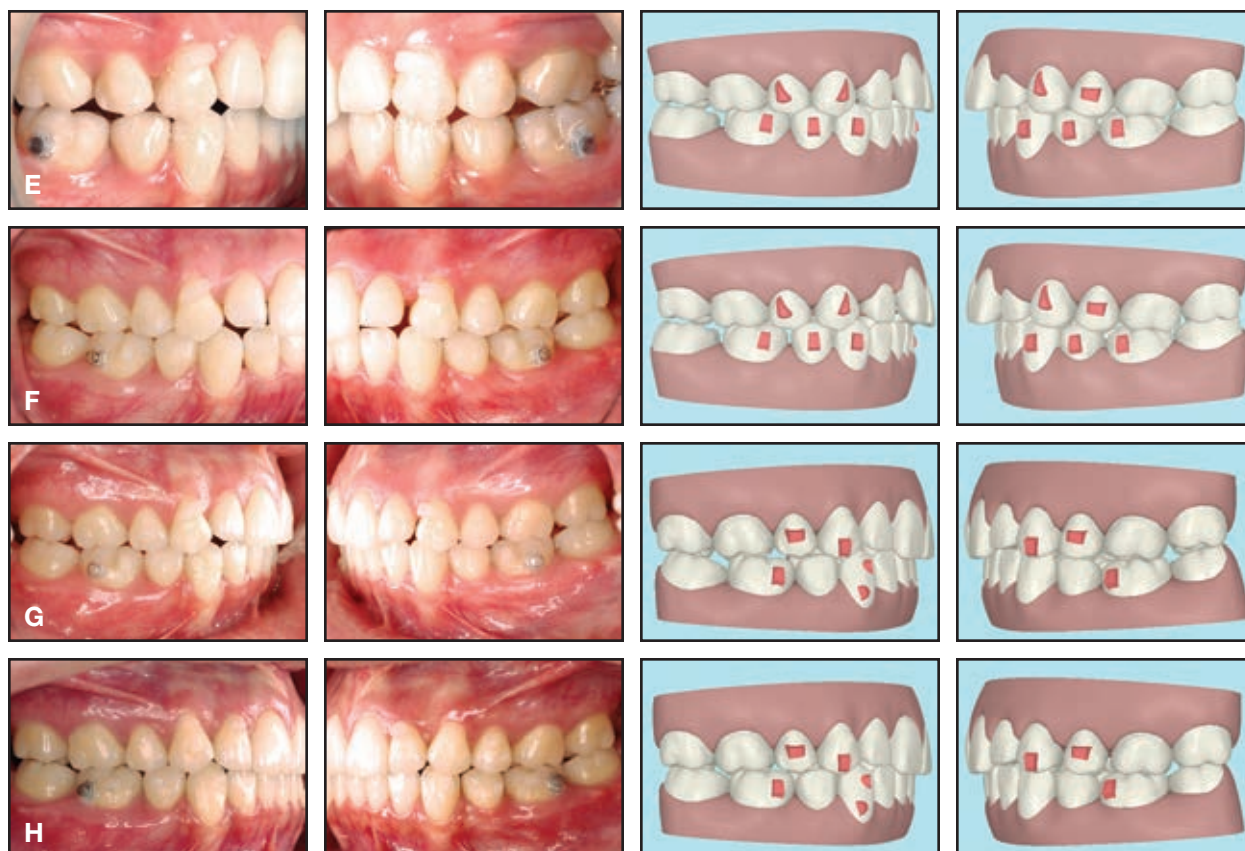

Fig. 6 (cont.) E. After nine months of treatment (aligner stage 54). F. After 10 months of treatment (aligner stage 60, end of first ClinCheck phase). G. After 13 months of treatment (refinement aligner stage 12). H. After 16 months of treatment (refinement aligner stage 25).

tachments to improve retention, leaving a margin of more than 2mm between the incisal edges and the aligners (Fig. 9). In the mandibular arch, which was serving as anchorage, the elastics were still not attached directly to the aligners, but to buttons on the buccal surfaces of the first molars. This kept the aligners from lifting off the teeth, while vertical rectangular attachments on the mesial edges of the molars prevented mesial angulation. To avoid tipping of the teeth adja-

cent to the mandibular extraction sites, we added vertical rectangular attachments that reduced the aligner movement to half the usual distance.²¹

Additional elastics were used to counteract palatal movement of the upper lateral incisors. Since the anatomical shape of the maxillary incisors makes it difficult to control their movement with aligners, we anticipated that only the incisor crowns would move labially once the patient's anterior crowding was

eliminated. Vertical rectangular attachments were added to the upper lateral incisors (on the lingual side for esthetic reasons) in the initial ClinCheck prescription, but the aligner fit over these teeth remained inadequate during the initial stages of treatment (Fig. 10A). Therefore, toward the end of refinement, an attachment was bonded near the gingival margin on the labial surface of each upper lateral incisor, and a metal button was bonded to the lingual surface. After inserting

Accelerated Extraction Treatment with Invisalign

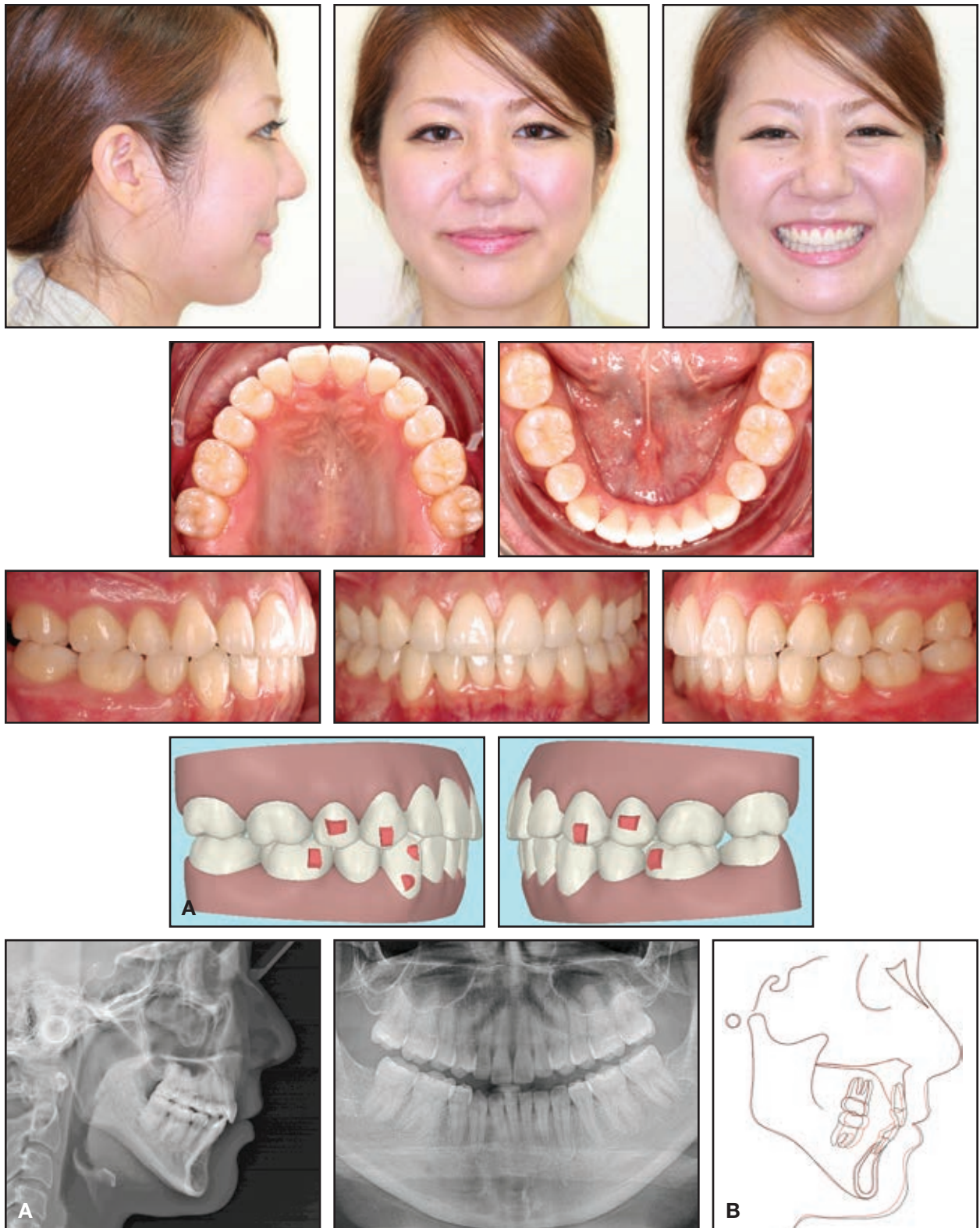


Fig. 7 A. Patient after 18 months of treatment. B. Superimposition of pre-and post-treatment cephalometric tracings.

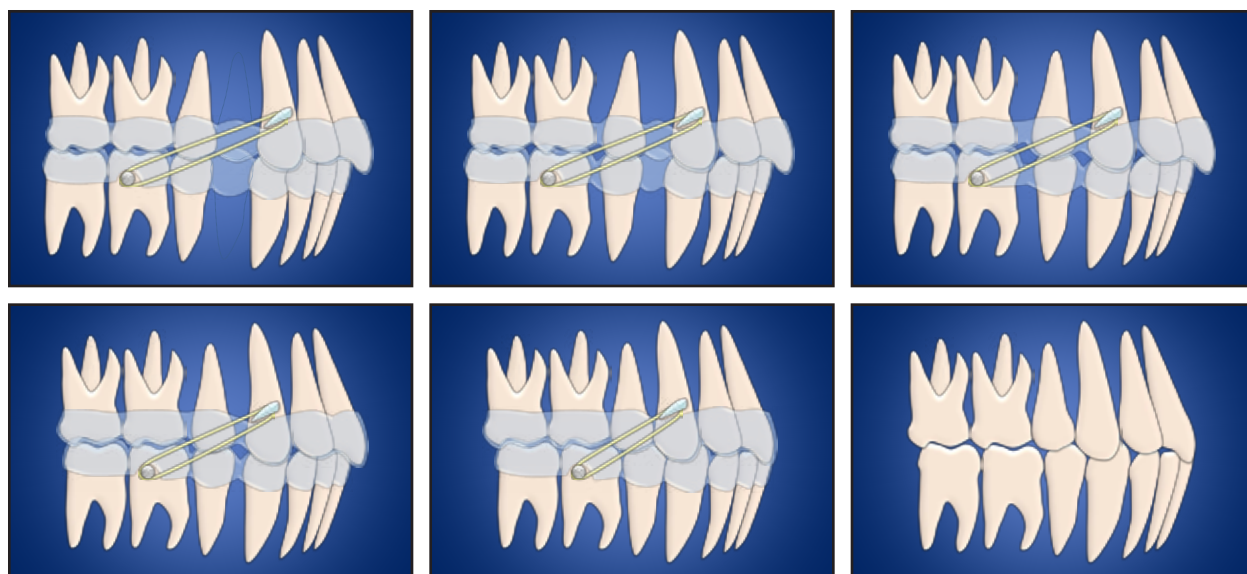


Fig. 8 Bowing effect avoided in extraction treatment with aligners by using Class II elastics to enhance intermaxillary anchorage.

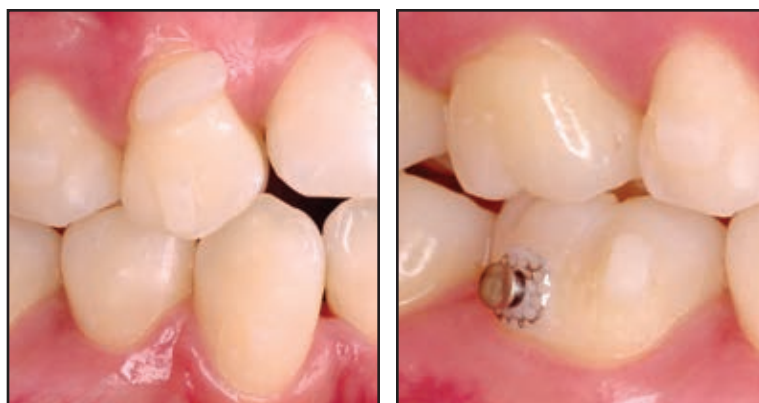

Fig. 9 Class II elastics worn to direct-bonded hook at gingival margin and vertical rectangular attachment on upper right first premolar in canine position (left) and to metal button and vertical rectangular attachment on lower right first molar (right).

the aligner, the patient looped elastics over the incisal edge of the appliance on each side, connecting the lingual buttons and the labial attachments. Three weeks later, the aligner fit at the lateral incisors had improved significantly (Fig. 10B,C).

To prevent tipping during the upper distal and lower mesial movement of the molars, we initially prescribed a slower staging that would have reduced the rate of tooth movement by half, to .15mm per aligner. The aligners would have been changed every

14 days over 30 months. Because that length of treatment was unacceptable to the patient, however, we elected to use AcceleDent**²²⁻²⁸ in conjunction with

**Registered trademark of OrthoAccel Technologies, Inc., Bellaire, TX; www.accelledent.com.

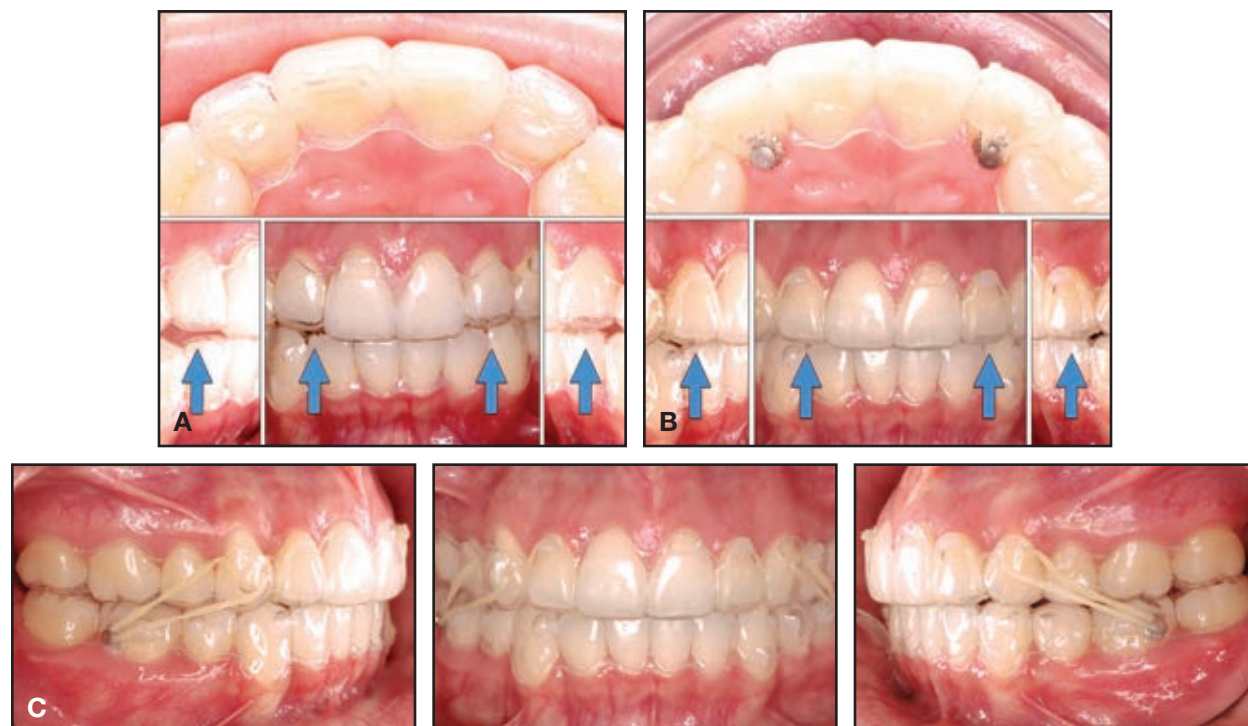

Fig. 10 A. Poor aligner fit over upper lateral incisors during initial phases of treatment. B. Lingual buttons and labial attachments on upper lateral incisors connected with elastics worn over aligner, improving aligner fit in three weeks. C. Esthetic appearance of aligners, Class II elastics, and upper-lateral-incisor elastics.



Fig. 11 AcceleDent in use.

the aligners. Although published accounts of the device's effectiveness were limited to fixed appliances at that point, we prescribed its use for 20 minutes every evening (Fig. 11). According to the manufacturer, this daily microvibratory stimulation can speed up treatment by as much as 30%. We were able to shorten the interval between aligner changes to five days, resulting in a remarkably reduced treatment time of only 18 months. The patient experienced no discomfort from the AcceleDent device or from the faster aligner changes. She finished treatment with no

interferences in protrusive or lateral mandibular movements and no esthetic concerns.

Conclusion

Aligners are not only esthetically pleasing to adult patients but, because they are easily removed, extremely safe. In the future, aligners are likely to be used in even more complex cases involving rotations, deep overbites, open bites, and unusual extractions.^{6,29-33} Further clinical investigations are needed into the effects of accelerated tooth movement in such cases.

REFERENCES

1. Vlaskalic, V. and Boyd, R.: Orthodontic treatment of a mildly crowded malocclusion using the Invisalign System, *Austral. Orthod. J.* 17:41-46, 2001.
2. Boyd, R.L.; Miller, R.J.; and Vlaskalic, V.: The Invisalign system in adult orthodontics: Mild crowding and space closure cases, *J. Clin. Orthod.* 34:203-212, 2000.
3. Giancotti, A. and Di Girolamo, R.: Treatment of severe maxillary crowding using Invisalign and fixed appliances, *J. Clin. Orthod.* 43:583-589, 2009.
4. Schupp, W.; Haubrich, J.; and Hermens, E.: Möglichkeiten und Grenzen der Schienentherapie in der Kieferorthopädie, *Zahnmed. Update* 2, 2013, pp. 171-184.
5. Schupp, W.; Haubrich, J.; and Neumann, I.: Treatment of anterior open bite with the Invisalign system, *J. Clin. Orthod.* 44:501-507; 2010.
6. Guarneri, M.P.; Oliverio, T.; Silvestre, I.; Lombardo, L.; and Siciliani, G.: Open bite treatment using clear aligners, *Angle Orthod.* 83:913-919, 2013.
7. Krieger, E.; Seiferth, J.; Marinello, I.; Jung, B.A.; Wriedt, S.; Jacobs, C.; and Wehrbein, H.: Invisalign treatment in the anterior region, *J. Orofac. Orthop.* 73:365-376, 2012.
8. Giancotti, A. and Farina, A.: Treatment of collapsed arches using the Invisalign system, *J. Clin. Orthod.* 44:416-425, 2010.
9. Fiorillo, G.; Festa, F.; and Grassi, C.: Upper canine extraction in adult cases with unusual malocclusions, *J. Clin. Orthod.* 46:102-110, 2012.
10. Sachan, A. and Chaturvedi, T.P.: Orthodontic management of buccally erupted ectopic canine with two case reports, *Contemp. Clin. Dent.* 3:123-128, 2012.
11. Boyd, R.L.: Esthetic orthodontic treatment using the Invisalign appliance for moderate to complex malocclusions, *J. Dent. Educ.* 72:948-967, 2008.
12. Castroflorio, T.; Garino, F.; Lazzaro, A.; and Debernardi, C.: Upper-incisor root control with Invisalign appliances, *J. Clin. Orthod.* 47:346-351, 2013.
13. Hahn, W.; Zapf, A.; Dathe, H.; Fialka-Fricke, J.; Fricke-Zech, S.; Gruber, R.; Kubein-Meesenburg, D.; and Sadat-Khonsari, R.: Torquing an upper central incisor with aligners: Acting forces and biomechanical principles, *Eur. J. Orthod.* 32:607-613, 2010.
14. Schupp, W.; Haubrich, J.; and Neumann, I.: Invisalign treatment of patients with craniomandibular disorders, *Int. Orthod.* 8:253-267, 2010.
15. Womack, W.R.: Four-premolar extraction treatment with Invisalign, *J. Clin. Orthod.* 40:493-500, 2006.
16. Miller, K.B.; McGorray, S.P.; Womack, R.; Quintero, J.C.; Perelmuter, M.; Gibson, J.; Dolan, T.A.; and Wheeler, T.T.: A comparison of treatment impacts between Invisalign aligner and fixed appliance therapy during the first week of treatment, *Am. J. Orthod.* 131:302e1-9, 2007.
17. Boyd, R.L.: Complex orthodontic treatment using a new protocol for the Invisalign appliance, *J. Clin. Orthod.* 41:525-547, 2007.
18. Vlaskalic, V. and Boyd, R.L.: Clinical evolution of the Invisalign appliance, *J. Calif. Dent. Assoc.* 30:769-776, 2002.
19. Hönn, M. and Göz, G.: A premolar extraction case using the Invisalign system, *J. Orofac. Orthop.* 67:385-394, 2006.
20. Giancotti, A.; Greco, M.; and Mampieri, G.: Extraction treatment using Invisalign technique, *Prog. Orthod.* 7:32-43, 2006.
21. Schupp, W.; Haubrich, J.; and Neumann, I.: Class II correction with the Invisalign system, *J. Clin. Orthod.* 44:28-35, 2010.
22. Kau, C.H.: A radiographic analysis of tooth morphology following the use of a novel cyclical force device in orthodontic, *Head Face Med.* 7:14, 2011.
23. Kau, C.H.: A novel device in orthodontics, *Aesthet. Dent. Today* 3:42-43, 2009.
24. Kau, C.H.; Nguyen, J.T.; and English, J.D.: The clinical evaluation of a novel cyclical force generating device in orthodontics, *Orthod. Prac.* 1:43-44, 2010.
25. Nishimura, M.; Chiba, M.; Ohashi, T.; Sato, M.; Shimizu, Y.; Igarashi, K.; and Mitani, H.: Periodontal tissue activation by vibration: Intermittent stimulation by resonance vibration accelerates experimental tooth movement in rats, *Am. J. Orthod.* 133:572-583, 2008.
26. Werner, A.: Acceleration by vibration, *Orthod. Prod.*, August 2011, pp. 30-31.
27. Miles, P.; Smith, H.; Weyant, R.; and Rinchuse, D.J.: The effects of a vibrational appliance on tooth movement and patient discomfort: A prospective randomised clinical trial, *Austral. Orthod. J.* 28:213-218, 2012.
28. Darendeliler, M.A.; Zea, A.; Shen, G.; and Zoellner, H.: Effects of pulsed electromagnetic field vibration on tooth movement induced by magnetic and mechanical forces: A preliminary study, *Austral. Dent. J.* 52:282-287, 2007.
29. Fischer, K.: Invisalign treatment of dental Class II malocclusions without auxiliaries, *J. Clin. Orthod.* 44:665-672, 2010.
30. Frongia, G. and Castroflorio, T.: Correction of severe tooth rotations using clear aligners: A case report, *Austral. Orthod. J.* 28:245-249, 2012.
31. Eckhart, J.E.: Sequential MARA-Invisalign treatment, *J. Clin. Orthod.* 43:439-448, 2009.
32. Krieger, E.; Seiferth, J.; Saric, I.; Jung, B.A.; and Wehrbein, H.: Accuracy of Invisalign treatments in the anterior tooth region: First results, *J. Orofac. Orthop.* 72:141-149, 2011.
33. Keim, R.G.: The Editor's Corner: Game changers in orthodontics, *J. Clin. Orthod.* 46:257-258, 2012.