

Julia Haubrich, Werner Schupp

# Open bite treatment with aligner orthodontics



Julia Haubrich

**KEY WORDS** aligner orthodontics, attachments, Dental Motion Decoder-System software, extrusion, in-office aligners, interdisciplinary dentistry, intrusion, Invisalign, OnyxCeph Aligner 3D software, open bite, virtual articulator

*The approach used to treat open bite depends on the origin of the anomaly and the Angle classification. This vertical deviation can be dental or skeletal in nature, or both combined. If removable appliances, such as an oral vestibular plate, or palatal expansion and myofunctional therapy are used in early treatments, multibracket therapy, extraction therapy or orthodontic treatment in combination with surgery are most used in the permanent dentition. Aligner therapy offers a valuable alternative approach for treating dentoalveolar open bite, and its use in combination with skeletal anchorage broadens the spectrum of orthodontics even more. The present article shows different examples of open bite patients treated with aligner orthodontics alone and discusses the incorporation of virtual articulators in treatment planning.*

## Introduction

Dentoalveolar open bite can be caused by genetics, dysfunctional swallowing, speech disorders, oral habits or mouth breathing due to enlarged lymphatic tissues or aller-

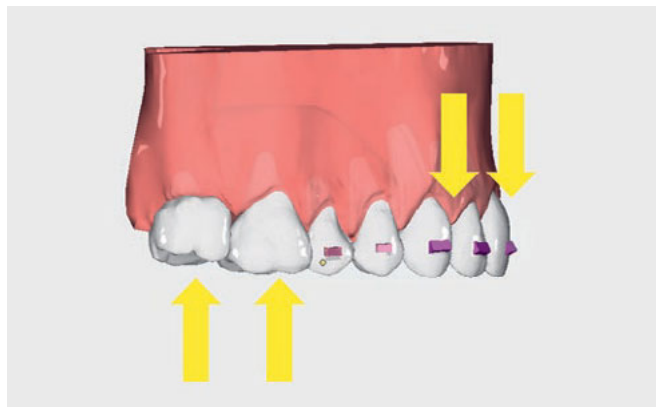
gies<sup>1</sup>. The positioning of the tongue during swallowing and speech and when at rest plays a major role in the development of open bite, aside from any genetic predispositions<sup>2-4</sup>. Kasparaviciene et al<sup>5</sup> found that 71.4% of the children included in their study presented with one or more attributes of malocclusion and 16.9% displayed oral habits. They found that digit suckers have a higher incidence of anterior open bite and posterior reverse articulation<sup>5</sup>. The infantile swallow pattern demonstrated a strong association with anterior open bite<sup>5</sup>. In open bite patients, communication between the orthodontist, otorhinolaryngologist and myofunctional therapist becomes necessary before and during orthodontic treatment, as the treatment result cannot be obtained or remain stable with dysfunctional oral muscles<sup>6</sup>.

Treatment for open bite can be approached in different ways. In 2010, the present authors published the first article on treatment for anterior open bite using the Invisalign system (Align Technology, San Jose, CA, USA), also considering the necessity of posterior intrusion in cases of anterior open bite<sup>7</sup>. Giancotti et al<sup>8</sup>, Pokorna et al<sup>9</sup> and Moshiri et al<sup>10</sup> also discussed bite closure in cases of anterior open bite with molar and incisor extrusion. Several authors have described combining orthodontic treatment with other orthodontic appliances<sup>11</sup> or skeletal anchorage in the past<sup>12-14</sup>. Dayan et al<sup>12</sup> presented a case of open bite treatment with aligner orthodontics combined with skeletal posterior intrusion, as did Ojima et al<sup>15</sup>. Greco et al<sup>16</sup> believe it

Julia Haubrich, Dr med dent  
Private practice, Cologne, Germany

Werner Schupp, Dr med dent  
Private practice, Cologne, Germany

**Correspondence to:** Dr Werner Schupp, Hauptstrasse 50, 50996 Cologne, Germany. Email: schupp@schupp-ortho.de



**Fig 1** Example of treatment with a combination of extrusion of anterior teeth with extrusion attachments and intrusion of posterior teeth (demonstrated in OnyxCeph Aligner 3D software [Image Instruments, Chemnitz, Germany]).

is important to simplify the approach to open bite treatment with aligners and selective micro-osteoperforations.

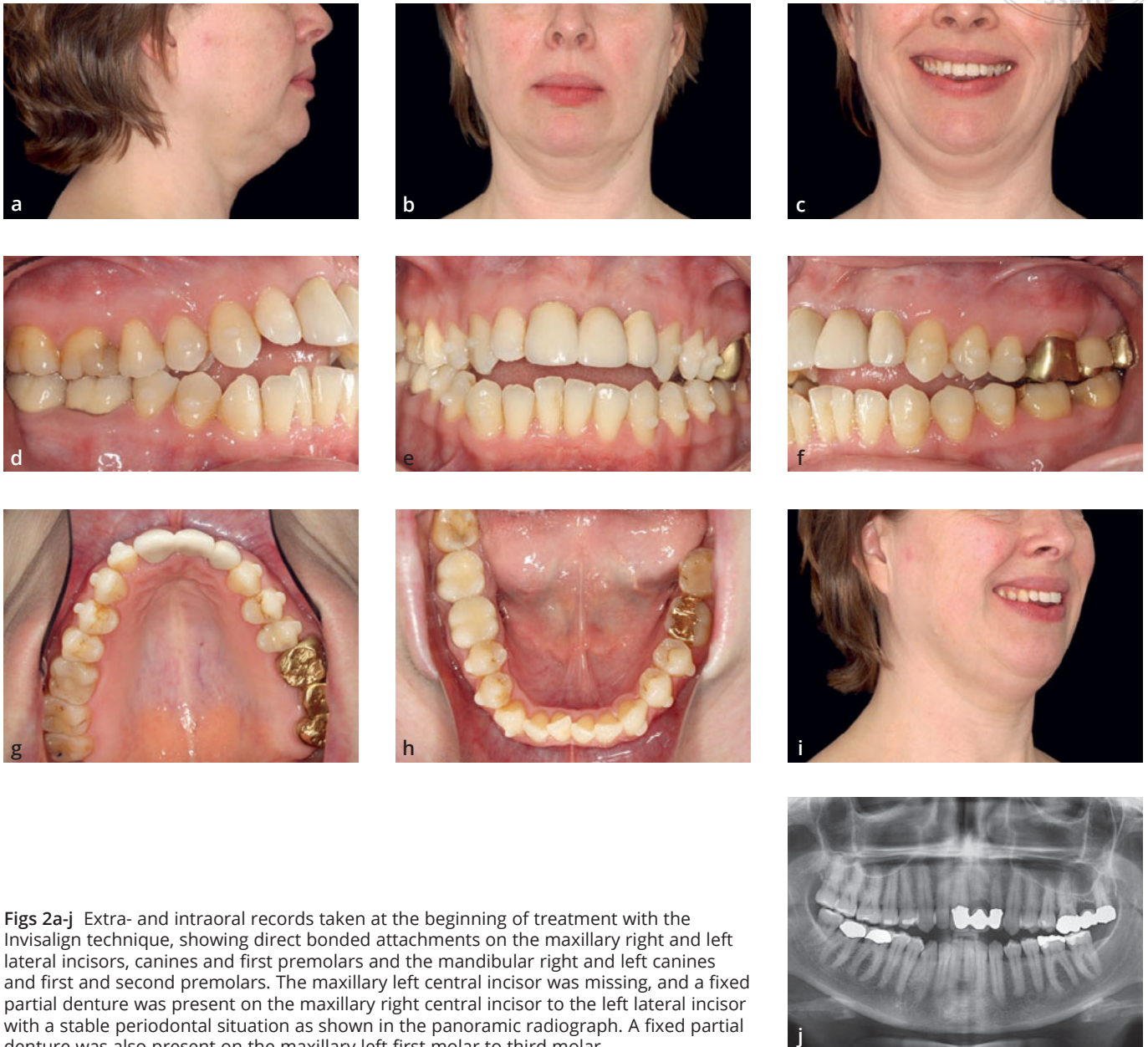In cases of excessive gingival display, further extrusion should be avoided for aesthetic reasons, but patients with little incisor display when at rest can be easily identified with the “Emma” picture according to Zachrisson<sup>17</sup> and the situation can be improved with anterior extrusion. When treating anterior open bite, good use can be made of the pressure biomechanics transferred with aligners by intruding the posterior teeth using attachments or engagers<sup>18</sup>. This results in tilting of the occlusal plane, and the subsequent mandibular autorotation leads to closure of the anterior open bite<sup>10,19</sup>. A significant advantage of open bite treatment with aligner orthodontics is that it avoids the use of up and down elastics in the anterior region; these are often employed in fixed appliance treatment. This makes it possible to minimise the danger of root resorption or gingival recession due to uncontrolled forces. The tendency for posterior teeth to be extruded in fixed appliance therapy<sup>20,21</sup> can be avoided in aligner orthodontics. Incisor extrusion through a tipping movement, such as in cases of protruded and spaced maxillary and mandibular anterior teeth, is somewhat easy to achieve with relative extrusion of anterior teeth with a combination of retrusive movements. Absolute extrusion is more difficult to achieve and takes more time. Although some treatments require anterior extrusion for bite closure only, in other cases, intrusion of the posterior teeth with a predictable counterclockwise rota-

tion of the mandible can help to obtain the desired result. A combination of anterior extrusion and posterior intrusion might be preferable in other patients (Fig 1). Lastly, when a greater amount of intrusion of the posterior teeth is necessary, application of skeletal anchorage with temporary anchorage devices (TADs) and additional elastic force for intrusion is the only possible way to avoid complex surgery<sup>22,23</sup>. The present article describes three treatments of three different patients, focusing on open bite treatment with aligner orthodontics alone without additional skeletal anchorage.

## Patient examples

### Patient 1: extrusion of maxillary anterior teeth

The 47-year-old patient attended the present authors' office with temporomandibular disorder (TMD), having been referred by an orthopaedist. After 6 months of temporomandibular splint therapy accompanied by manual therapy performed by the orthopaedist, the patient was pain-free and the orthodontic treatment began with the aim of improving the functional relation of the anterior teeth so new prosthetics could be placed in the maxillary anterior region from the maxillary right central incisor to the left lateral incisor. The patient initially showed an anterior open bite of 4 mm and a horizontal overlap of 6 mm with a slight Class II relationship on both sides (Fig 2). The maxillary left central incisor was missing, and a fixed partial denture was present on the maxillary right central incisor to the left lateral incisor with a stable periodontal situation as shown in the panoramic radiograph (Fig 2j). After myofunctional therapy to improve the swallowing muscle pattern, direct bonded attachments were placed on the maxillary lateral incisors, canines and first premolars and the mandibular canines and first and second premolars (Figs 2a to h). A scan was taken (iTero Element intraoral scanner, Align Technology) and transferred into the ClinCheck software (Align Technology) (Figs 3a to e). A virtual treatment plan was finalised, including 42 aligners in both arches. As the patient was pain-free, no change to the Class II relationship was envisaged, and the planned treatment outcome remained as a situation with an increased horizontal overlap. As a fixed partial denture was present on the maxillary right central incisor to the left lateral incisor, no separate movement of

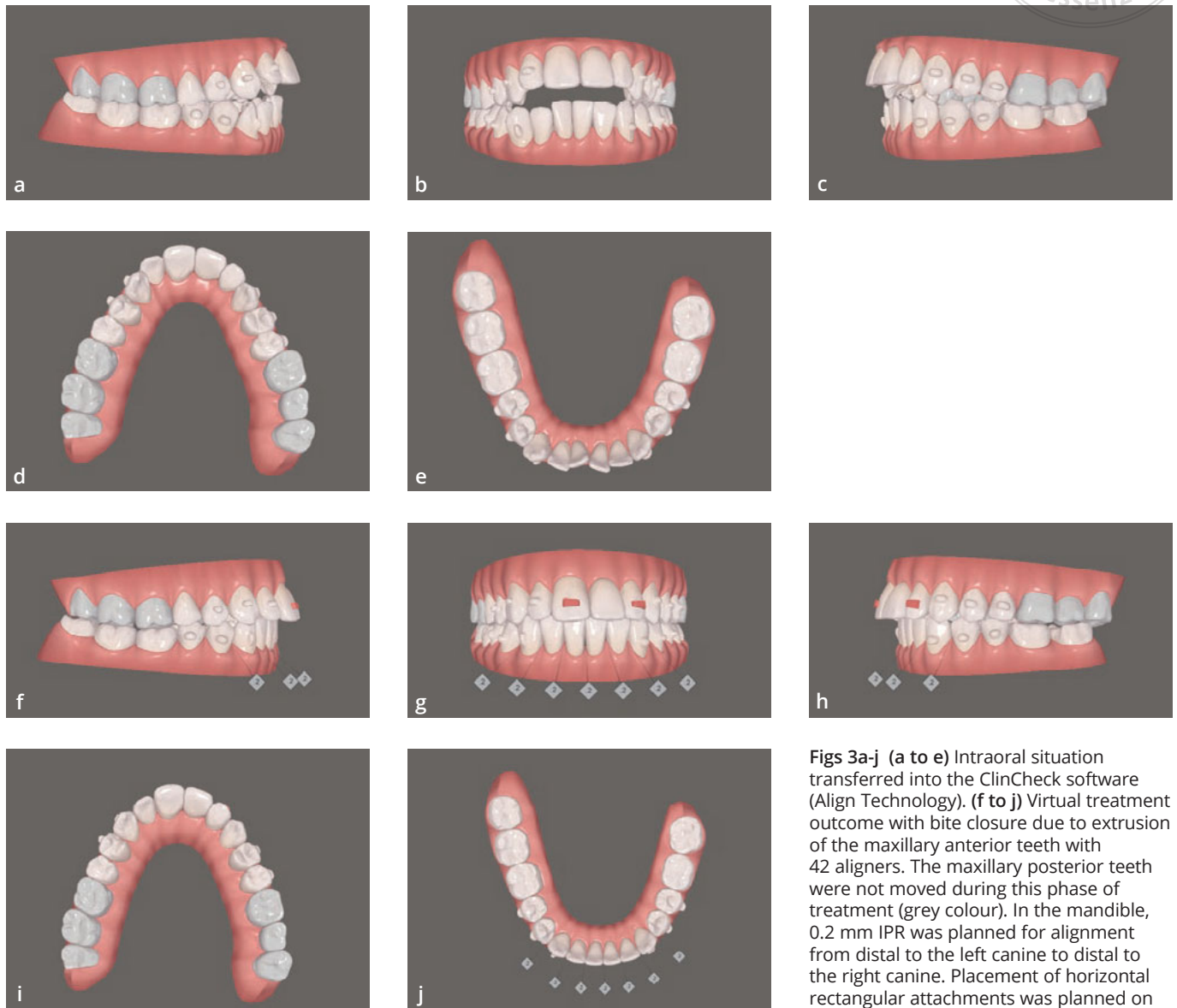


**Figs 2a-j** Extra- and intraoral records taken at the beginning of treatment with the Invisalign technique, showing direct bonded attachments on the maxillary right and left lateral incisors, canines and first premolars and the mandibular right and left canines and first and second premolars. The maxillary left central incisor was missing, and a fixed partial denture was present on the maxillary right central incisor to the left lateral incisor with a stable periodontal situation as shown in the panoramic radiograph. A fixed partial denture was also present on the maxillary left first molar to third molar.

teeth was possible, and the movement of the fixed partial denture as whole, including two roots, posed quite a challenge for orthodontic movement with aligners alone. As the patient wished to keep her existing fixed partial denture during aligner treatment, the treatment plan included the movement of the denture as a whole with extrusion and alignment of the mandibular anterior teeth without removing the partial denture (Fig 3). Figures 3f to j show the planned virtual treatment outcome with bite closure achieved exclusively due to extrusion of the maxillary an-

terior teeth. The posterior teeth were not moved during this phase of treatment (grey colour). For alignment in the mandible, 0.2 mm interproximal reduction (IPR) was planned from distal to the left canine to distal to the right canine. Placement of horizontal rectangular attachments was planned on the maxillary right central incisor and left lateral incisor, making it possible to apply extrusive force to the maxillary anterior fixed partial denture as a whole.

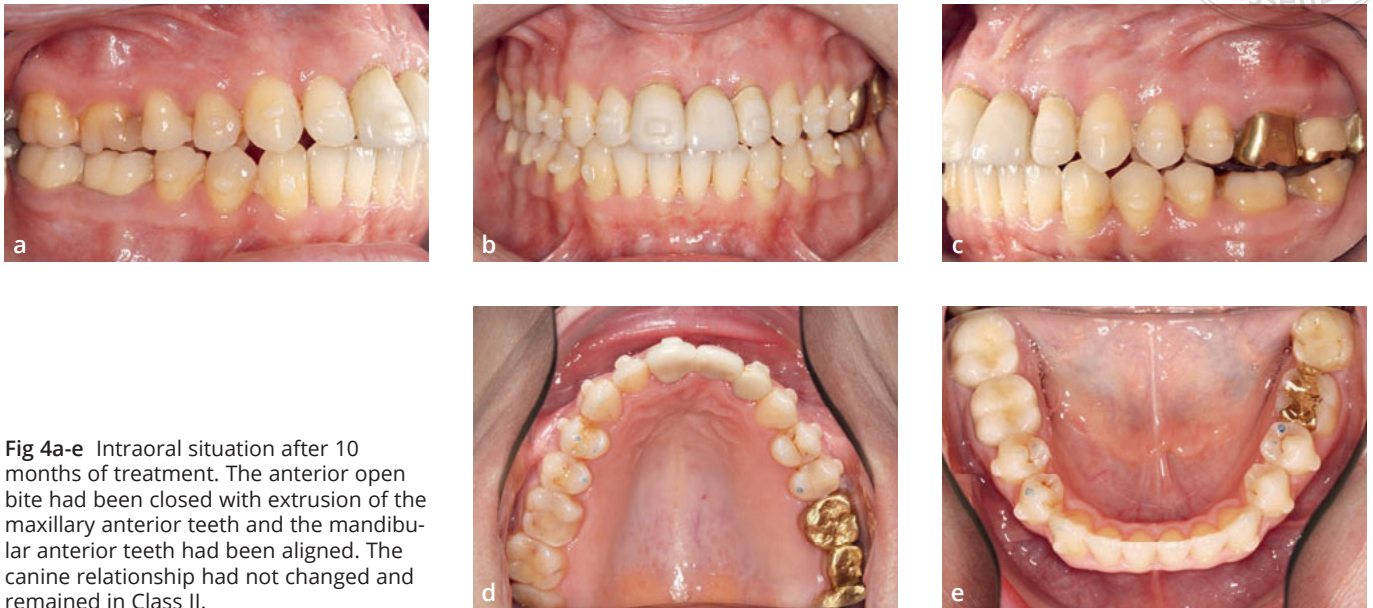
In Germany, there must be a medical reason and a justifying indication under the Ordinance on Protection against



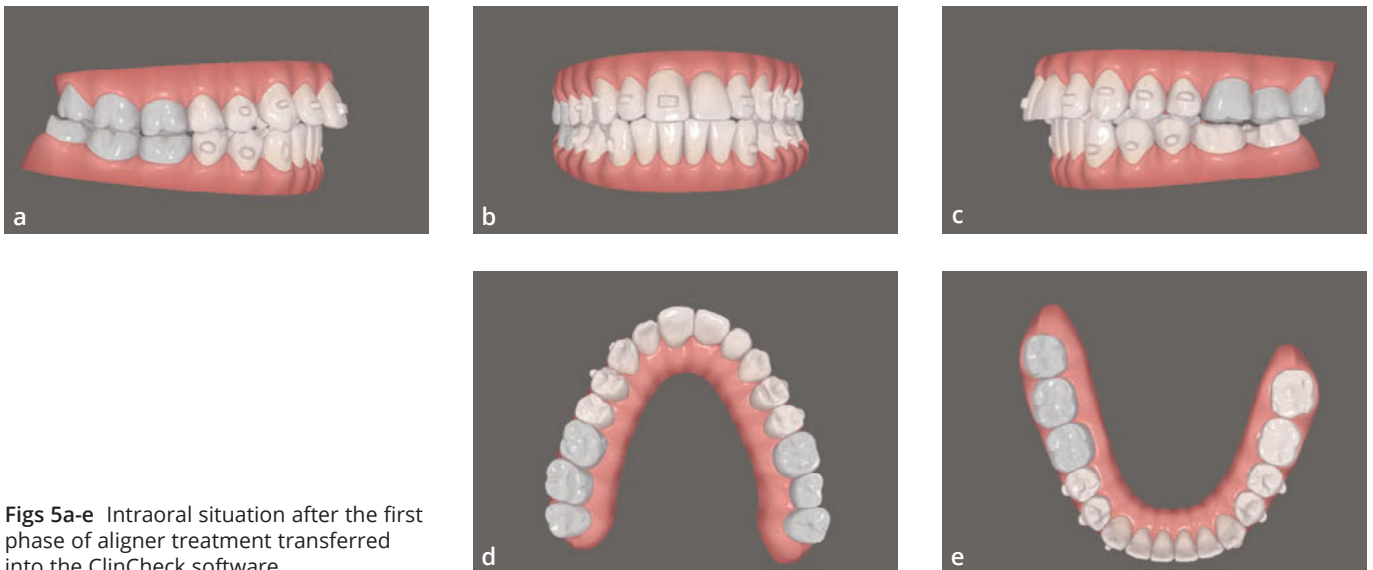
**Figs 3a-j** (a to e) Intraoral situation transferred into the ClinCheck software (Align Technology). (f to j) Virtual treatment outcome with bite closure due to extrusion of the maxillary anterior teeth with 42 aligners. The maxillary posterior teeth were not moved during this phase of treatment (grey colour). In the mandible, 0.2 mm IPR was planned for alignment from distal to the left canine to distal to the right canine. Placement of horizontal rectangular attachments was planned on the maxillary right central incisor and left lateral incisor, making it possible to apply extrusive force to the maxillary anterior fixed partial denture as a whole.

the Harmful Effects of Ionising Radiation (Federal German X-Ray Regulations) for radiographs to be taken. Radiographs cannot be taken for forensic reasons alone. Since surgical procedures were excluded in the treatment of the present patients, the present authors did not take cephalometric radiographs in order to adhere to the abovementioned regulation; thus, additional lateral cephalometric radiographs were not taken.

The patient started to wear her aligners and changed them weekly. Figure 4 shows the intraoral situation after 10 months of treatment and the improved anterior bite situation. Figure 5 presents the intraoral situation after the first phase of aligner treatment and the virtually planned second phase of treatment with further improvement of the canine relationship with 0.5 mm IPR mesial and distal of the maxillary first premolars to retract the maxillary anterior



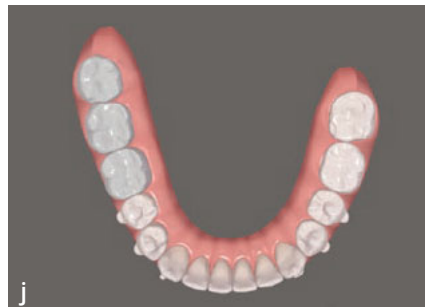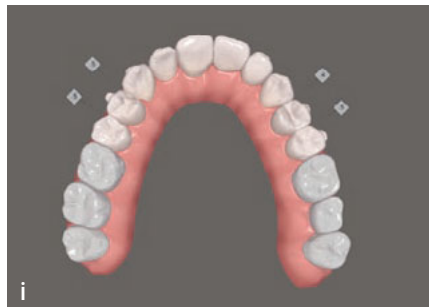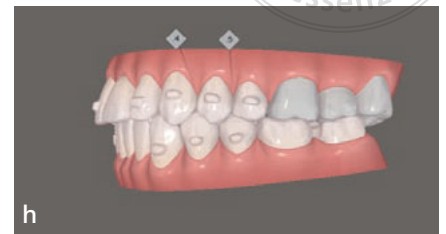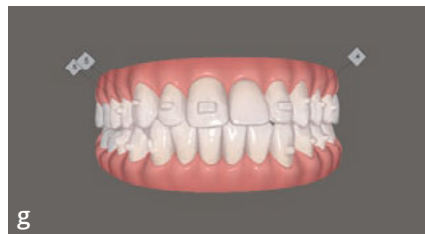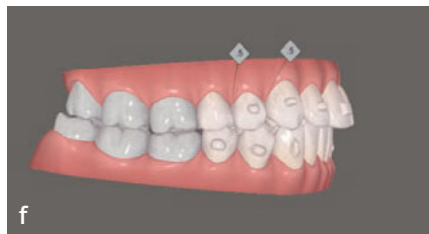**Fig 4a-e** Intraoral situation after 10 months of treatment. The anterior open bite had been closed with extrusion of the maxillary anterior teeth and the mandibular anterior teeth had been aligned. The canine relationship had not changed and remained in Class II.



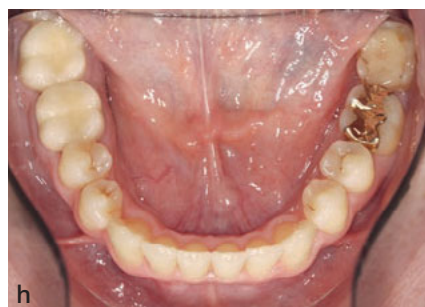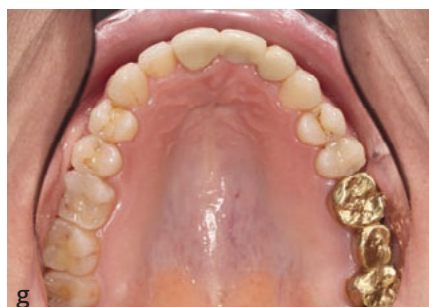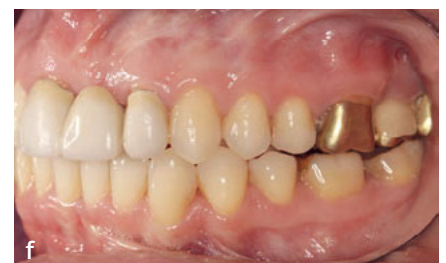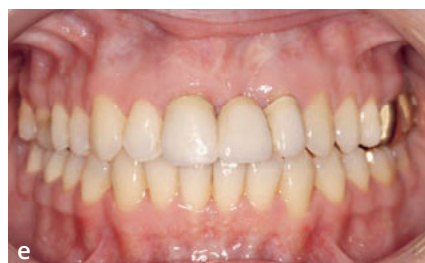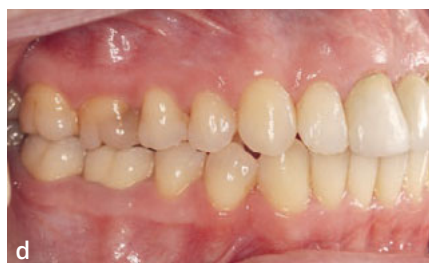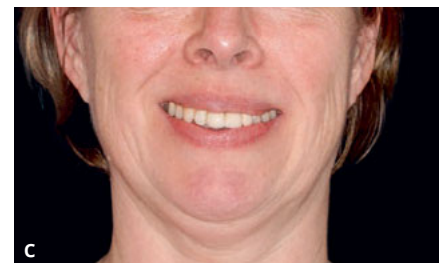
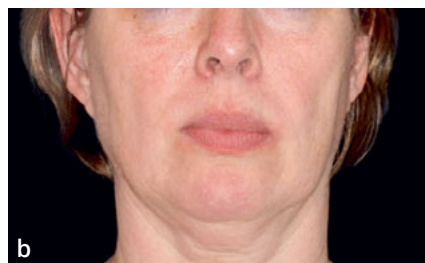
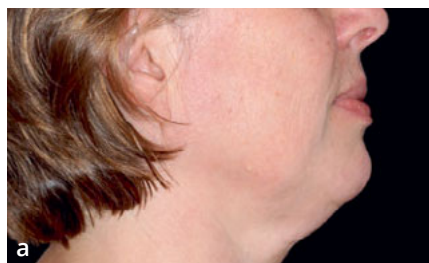**Figs 5a-e** Intraoral situation after the first phase of aligner treatment transferred into the ClinCheck software.

teeth and canines with an additional 10 aligners. A slight final midline deviation remained and was planned to be corrected with the new restorative fixed partial denture. Figure 6 shows the extra- and intraoral situation after completion of aligner treatment, with a closed anterior open bite and improved canine relationship. The result was maintained with an occlusal retention splint in the maxilla and a lingual retainer from the mandibular left first pre-

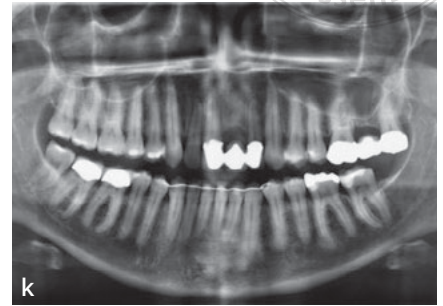
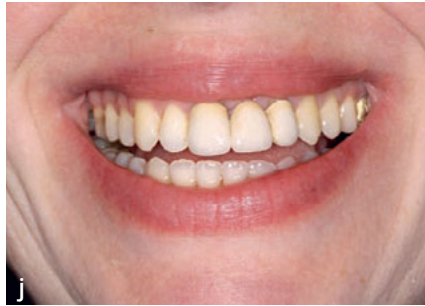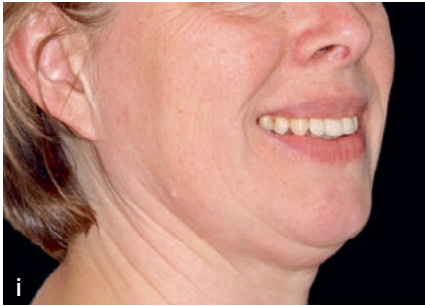molar to right first premolar. The panoramic radiograph revealed no pathologies. After 3 months of retention, a new fixed partial denture was inserted by the general dental practitioner (Dr U Meyer, Euskirchen). The extra- and intraoral situation after placement of this new partial denture on the maxillary right central incisor to the left lateral incisor with a harmonious smile and centred midlines are shown in Fig 7. Retention continued with the patient being advised



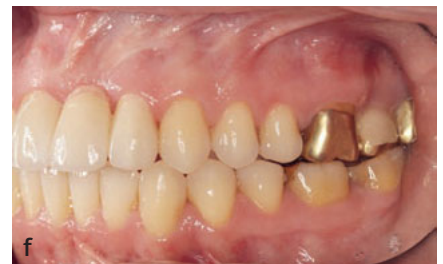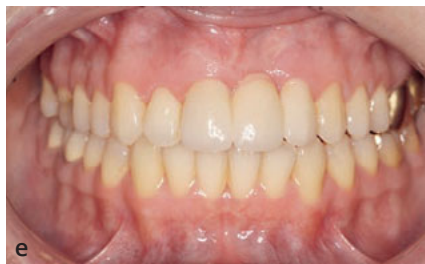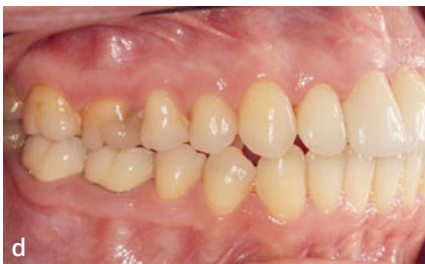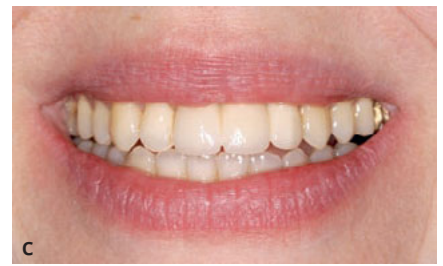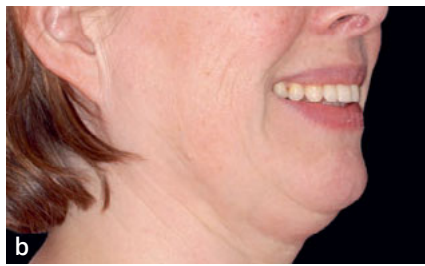
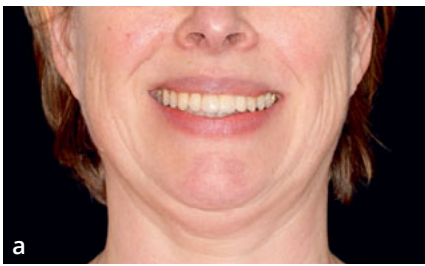**Figs 5f-j** The second phase of treatment included improvement of the canine relationship with 0.5 mm IPR mesial and distal of the maxillary first premolars to retract the maxillary anterior teeth and canines with an additional 10 aligners. A slight final midline deviation remained and was planned to be corrected with the new restorative fixed partial denture. Movement of the molars on the right side was not planned (grey colour), but the mandibular left molars were moved to improve occlusal contacts.



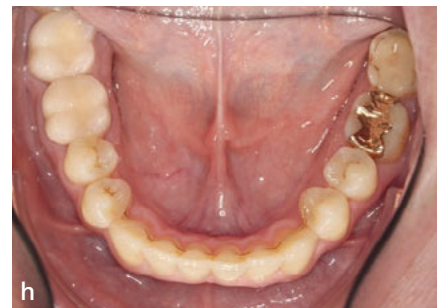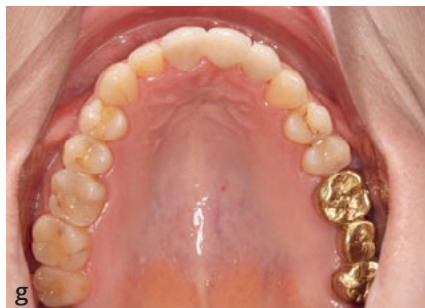**Figs 6a-h** Extra- and intraoral situation after completion of aligner treatment, with a closed anterior open bite and improved canine relationship. The result was maintained with the last aligner in the maxilla and a lingual retainer from the mandibular left first premolar to right first premolar. The panoramic radiograph revealed no pathologies.



Figs 6i-k (cont.)

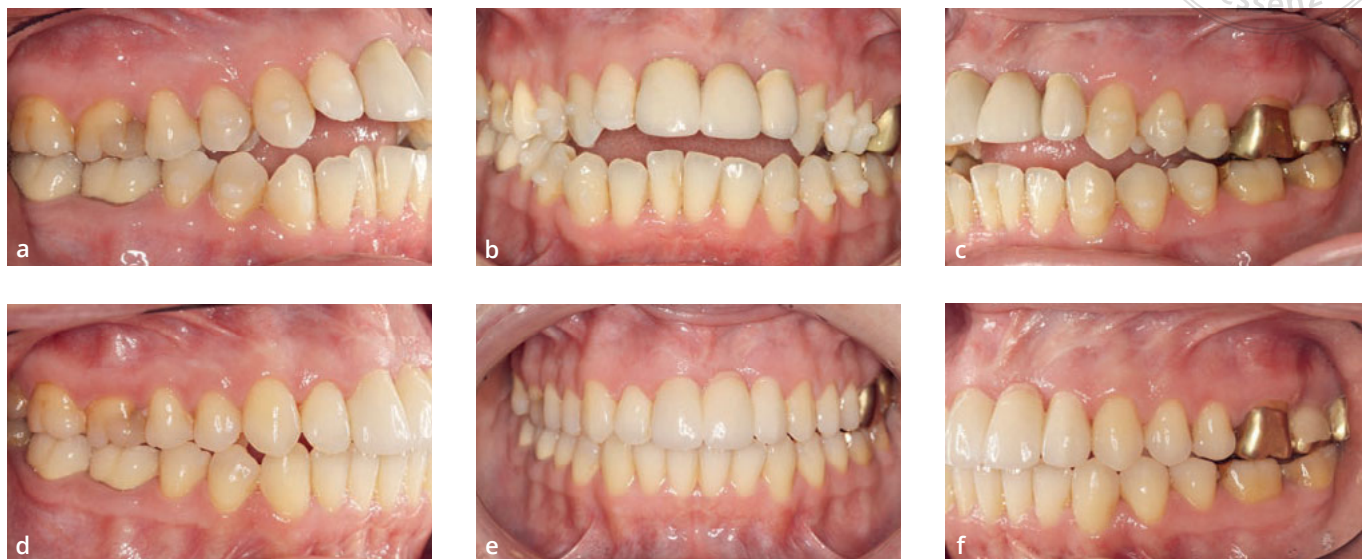

**Fig 7a-h** Extra- and intraoral situation after insertion of a new restorative fixed partial denture on the maxillary right central incisor to the left lateral incisor (Dr U Meyer, Euskirchen) with a harmonious smile and centred midlines. Retention continued with an occlusal retention splint for nighttime wear and a fixed retainer in the mandible.



to wear a removable maxillary aligner at night and a fixed mandibular retainer from the mandibular left first premolar to the right first premolar (five-stranded wire with a diameter of 0.0215 inches). A comparison of the pre- and

posttreatment situation is shown in Fig 8, demonstrating extrusion of the maxillary fixed partial denture achieved solely with aligner orthodontics.



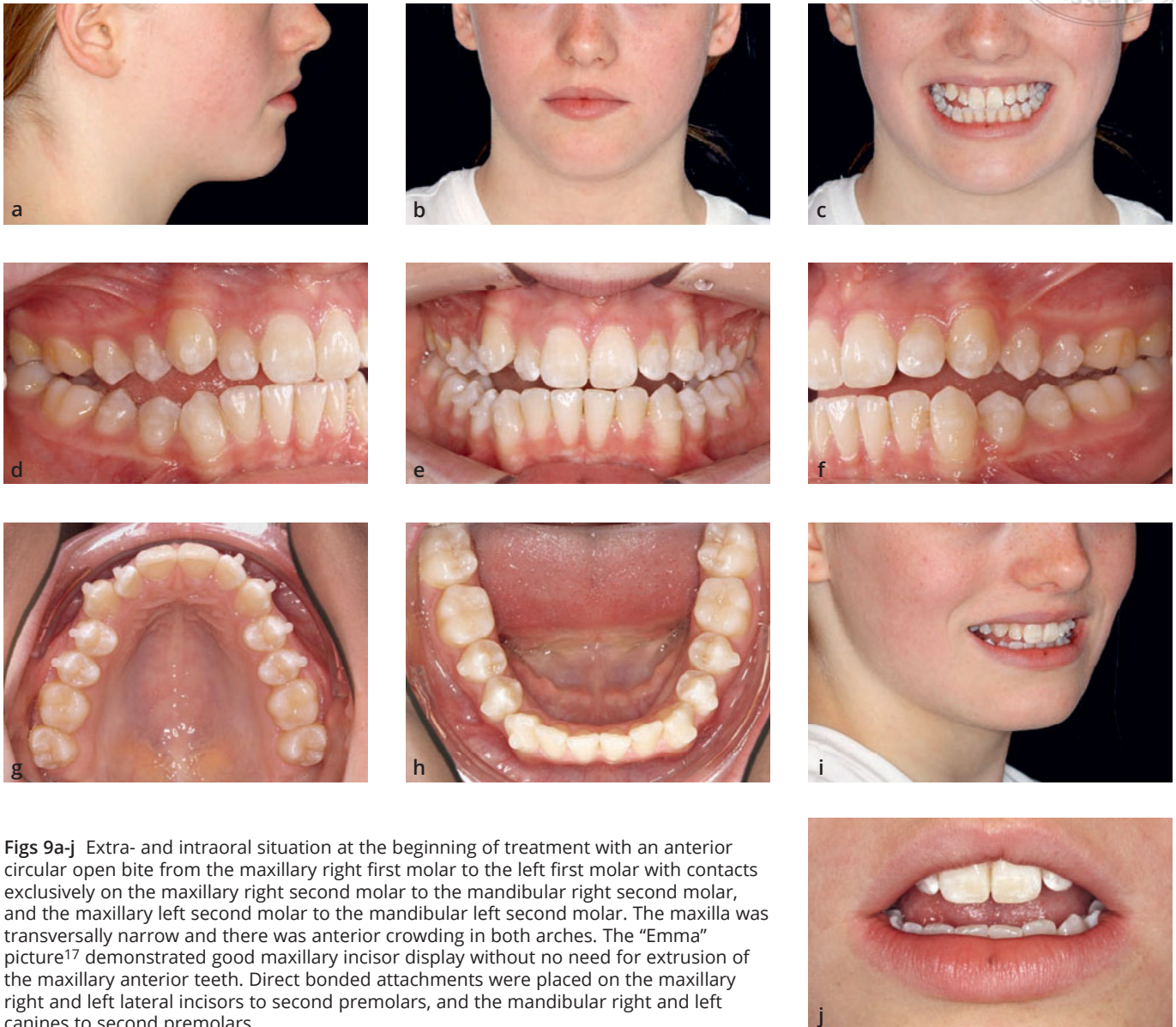**Figs 8a-f** Comparison before (a to c) and after (d to f) aligner treatment with extrusion of the maxillary anterior teeth and new restorations.

### Patient 2: intrusion of posterior teeth

The patient first attended the present authors' office at the age of 13 years, displaying an anterior circular open bite from the maxillary right first molar to the left first molar with overerupted second molars and contacts exclusively on the maxillary right second molar to the mandibular right second molar, and the maxillary left second molar to the mandibular left second molar (Fig 9). The maxilla was narrow due to a transverse discrepancy and there was anterior crowding in both arches. The midlines were slightly misaligned. The patient showed no signs of TMD. Myofunctional therapy was recommended as the patient demonstrated visceral tongue thrusting. Extraorally, she displayed a slightly retruded mandibular position with a good nasiolabial angle. The "Emma" picture<sup>17</sup> showing the display of teeth in the rest position demonstrated good maxillary incisor display with no need for extrusion of the maxillary anterior teeth (Fig 9j). Direct bonded attachments were placed on the maxillary right and left lateral incisors to second premolars, and the mandibular right and left canines to second premolars, and a scan was taken and transferred into the ClinCheck software (Figs 10a to e). The first treatment phase included transverse maxillary expansion with alignment of the anterior teeth, as well as 0.2 mm IPR from mesial to the left canine to mesial to the right canine to align the mandibular anterior teeth with 19 aligners. The main objective for this phase of treatment was to intrude all the second

molars, which led to a simulated posterior open bite without any occlusal contacts (Figs 10f to j). The absence of a virtual articulator in the ClinCheck software means that precise simulation of the potential occlusion after eliminating the first occlusal contacts on the second molars cannot be achieved (see the later section on virtual articulators). A virtual jump of the mandible according to the software can only offer insight into the potential final outcome after the first phase of treatment (Figs 10k to o, aligner stage 20). The patient changed her aligners every 7 days. After 20 weeks of treatment, new records were taken for finishing with an additional aligner phase (Fig 11). Figures 12a to e show the scan transferred into the ClinCheck software, with the anterior open bite having been closed but a Class II malocclusion remaining on the right side, persistent midline deviation and missing full occlusal contacts on the first molars. A precision cut (Align Technology) was inserted on the maxillary right canine and a button cutout was placed on the mandibular right first molar for unilateral Class II elastic wear. Horizontal rectangular attachments were planned on the mesial aspects of the mandibular first molars to angulate and extrude the crowns into occlusal contact. Power ridges (Align Technology) were planned on the maxillary and mandibular central incisors for additional root torque and optimal functional horizontal overlap. Figures 12f to j show the final planned outcome after an additional 20 aligners.

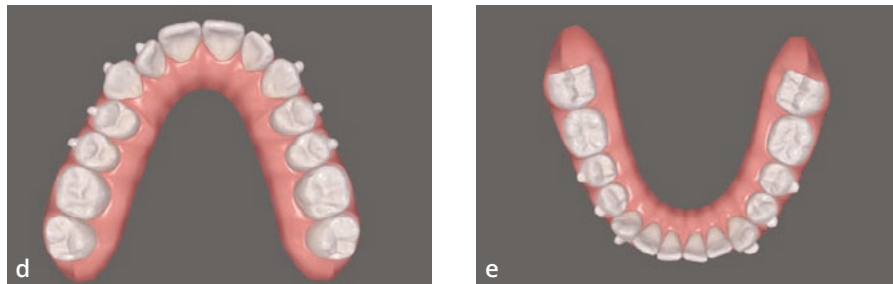
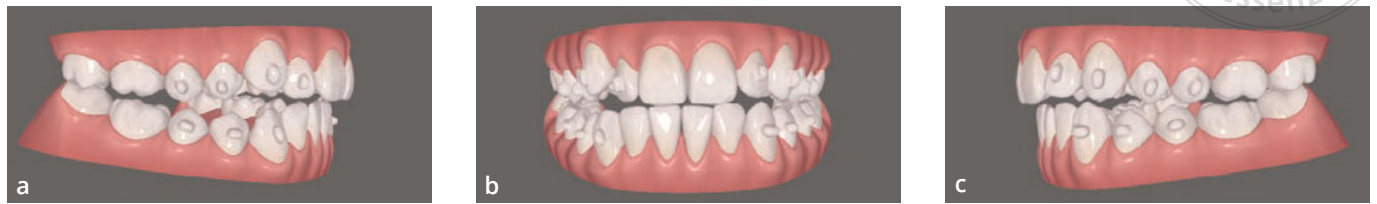



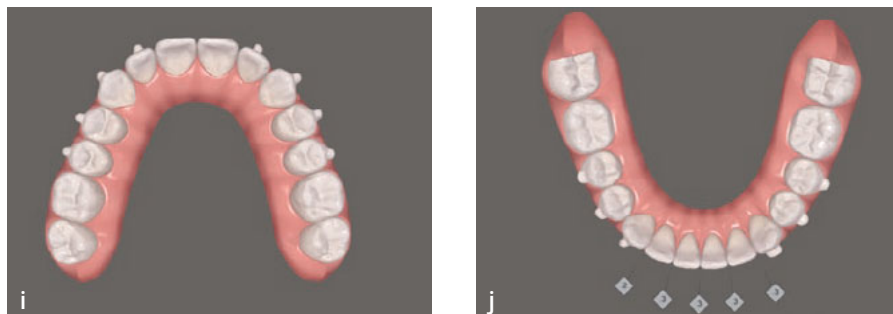
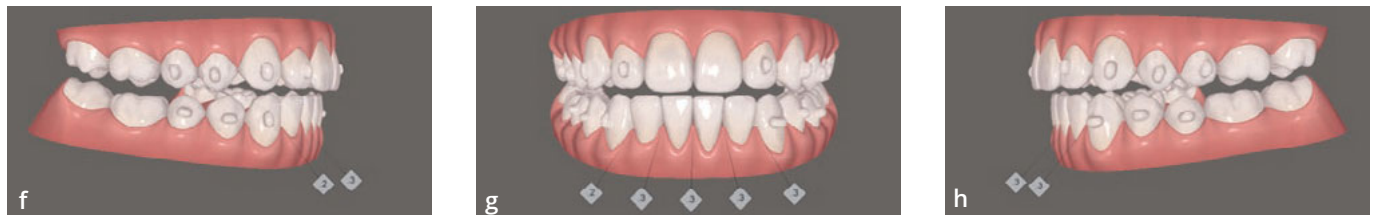
**Figs 9a-j** Extra- and intraoral situation at the beginning of treatment with an anterior circular open bite from the maxillary right first molar to the left first molar with contacts exclusively on the maxillary right second molar to the mandibular right second molar, and the maxillary left second molar to the mandibular left second molar. The maxilla was transversally narrow and there was anterior crowding in both arches. The “Emma” picture<sup>17</sup> demonstrated good maxillary incisor display without no need for extrusion of the maxillary anterior teeth. Direct bonded attachments were placed on the maxillary right and left lateral incisors to second premolars, and the mandibular right and left canines to second premolars.

Figure 13 demonstrates the final extra- and intraoral situation with a harmonious profile and full smile. Intraorally, the patient showed a full Class I relationship with aligned midlines and functional horizontal and vertical overlap. The “Emma” picture<sup>17</sup> showed no change to the vertical incisor display, as planned. The final panoramic radiograph displayed no pathologies, and further control of the third molars was advised.

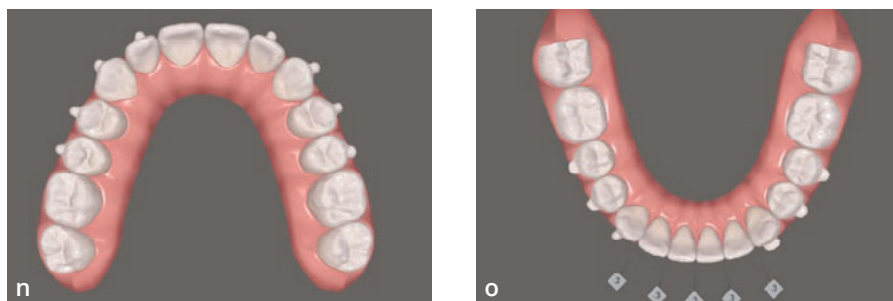
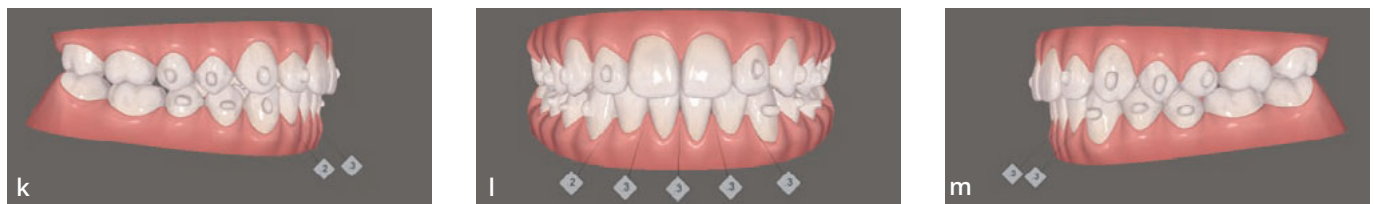
After an overall aligner treatment time of 40 weeks, the treatment was finished and lingual retainers were bonded from the maxillary right canine to the left canine and the mandibular left first premolar to the right first premolar (Fig 14), which the present authors usually recommend as the retention method of choice after open bite treatment. Figure 15 shows the course of treatment with intrusion of the posterior teeth with aligners only.



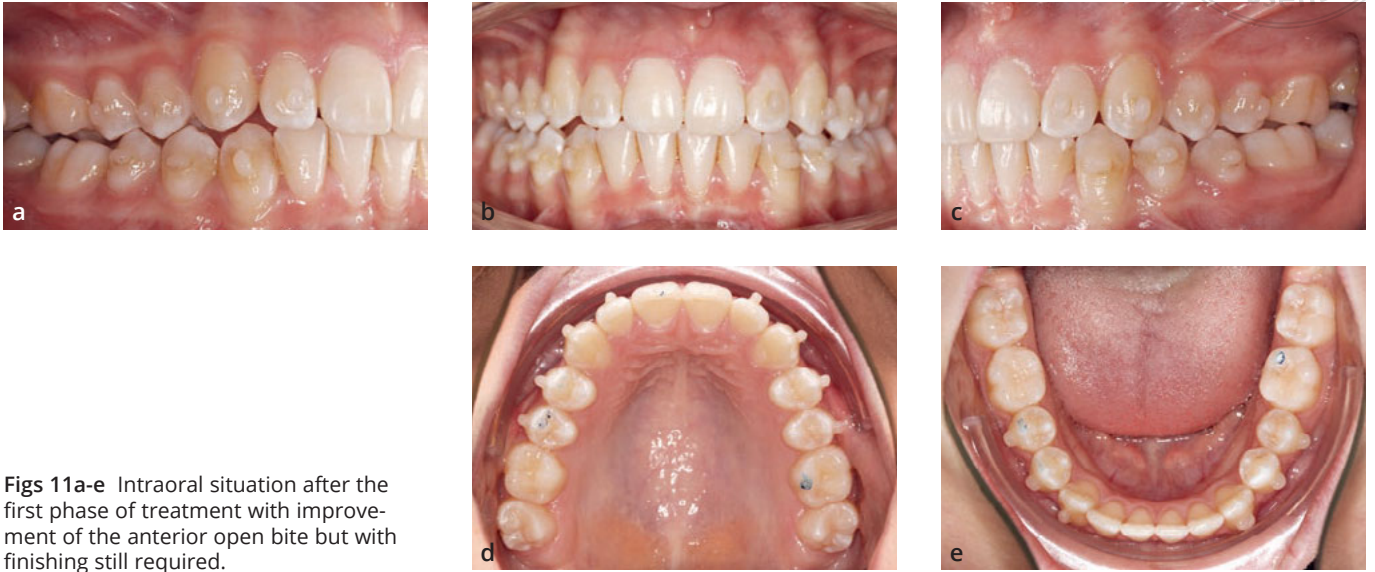**Figs 10a-o** Simulation in the ClinCheck software. (a to e) Initial intraoral situation transferred into the ClinCheck software.



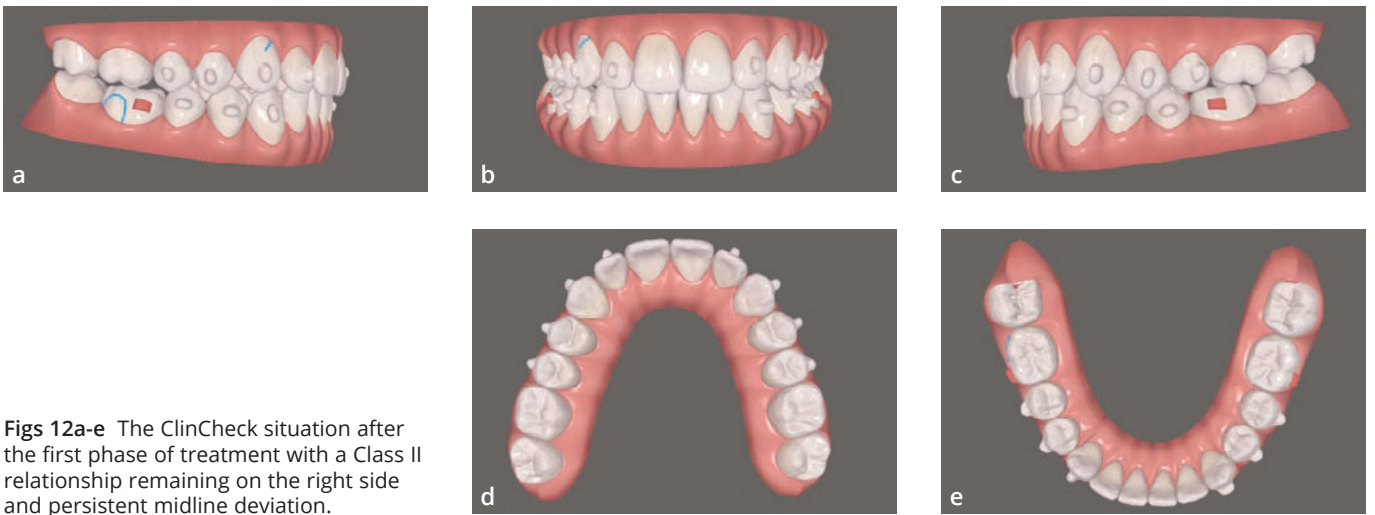
**Figs 10f to j** Virtual treatment simulation (VTS) after alignment of arches with maxillary expansion and IPR on the mandibular teeth from mesial to the left canine to mesial to the right canine. Due to the planned intrusion of the posterior teeth, all occlusal contacts were eliminated and there was an anterior open bite.



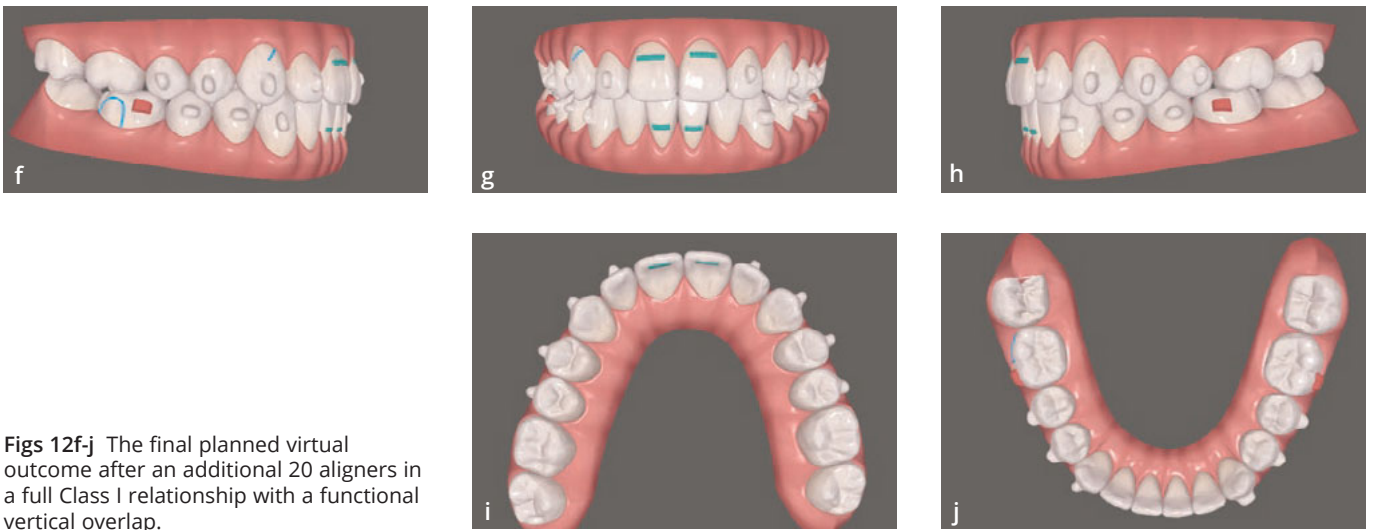
**Figs 10k to o** The virtually simulated outcome with potential setting of the mandible in occlusal contact but without relying on a realistic hinge axis.



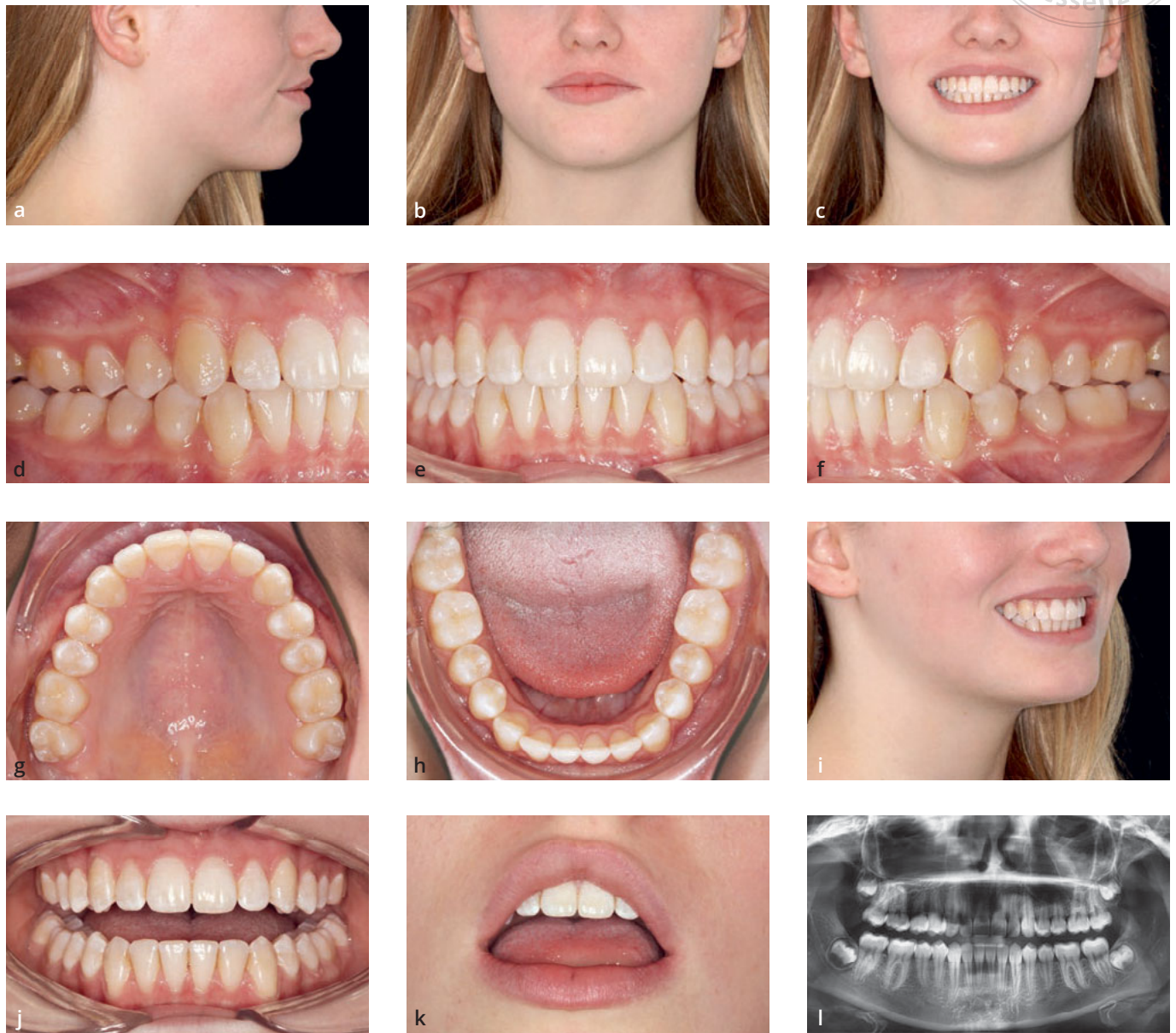
**Figs 11a-e** Intraoral situation after the first phase of treatment with improvement of the anterior open bite but with finishing still required.



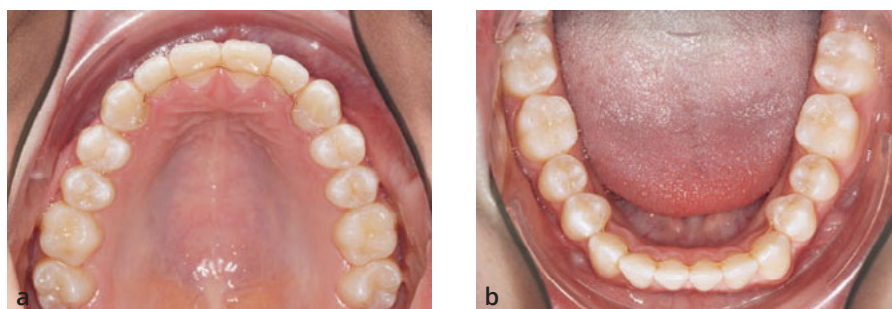
**Figs 12a-e** The ClinCheck situation after the first phase of treatment with a Class II relationship remaining on the right side and persistent midline deviation.



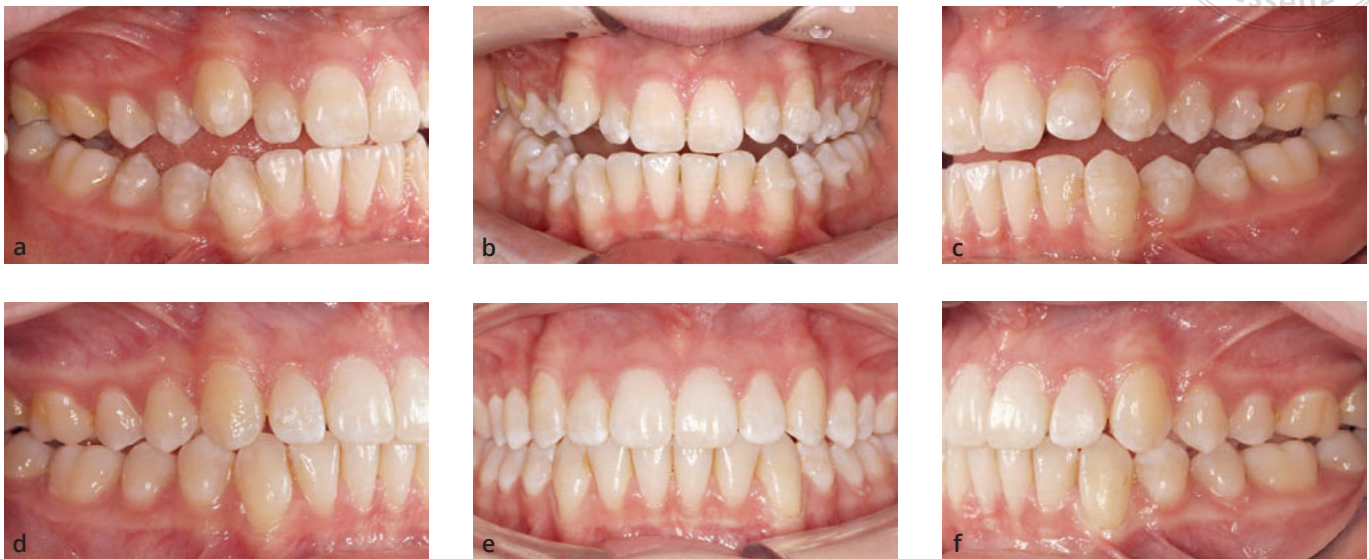**Figs 12f-j** The final planned virtual outcome after an additional 20 aligners in a full Class I relationship with a functional vertical overlap.



**Figs 13a-l** Final extra- and intraoral situation with a harmonious profile and full smile. Intraorally, the patient showed a full Class I relationship with aligned midlines and functional horizontal and vertical overlap. The “Emma” picture<sup>17</sup> showed no change to the vertical incisor display, as planned. The final panoramic radiograph revealed no pathologies, and further control of the third molars was advised.



**Figs 14a-b** Lingual retainers were bonded from the maxillary right canine to left canine and the mandibular left first premolar to right first premolar.



Figs 15a-f Comparison of the situation before (a to c) and after (d to f) aligner treatment and intrusion of the posterior teeth.

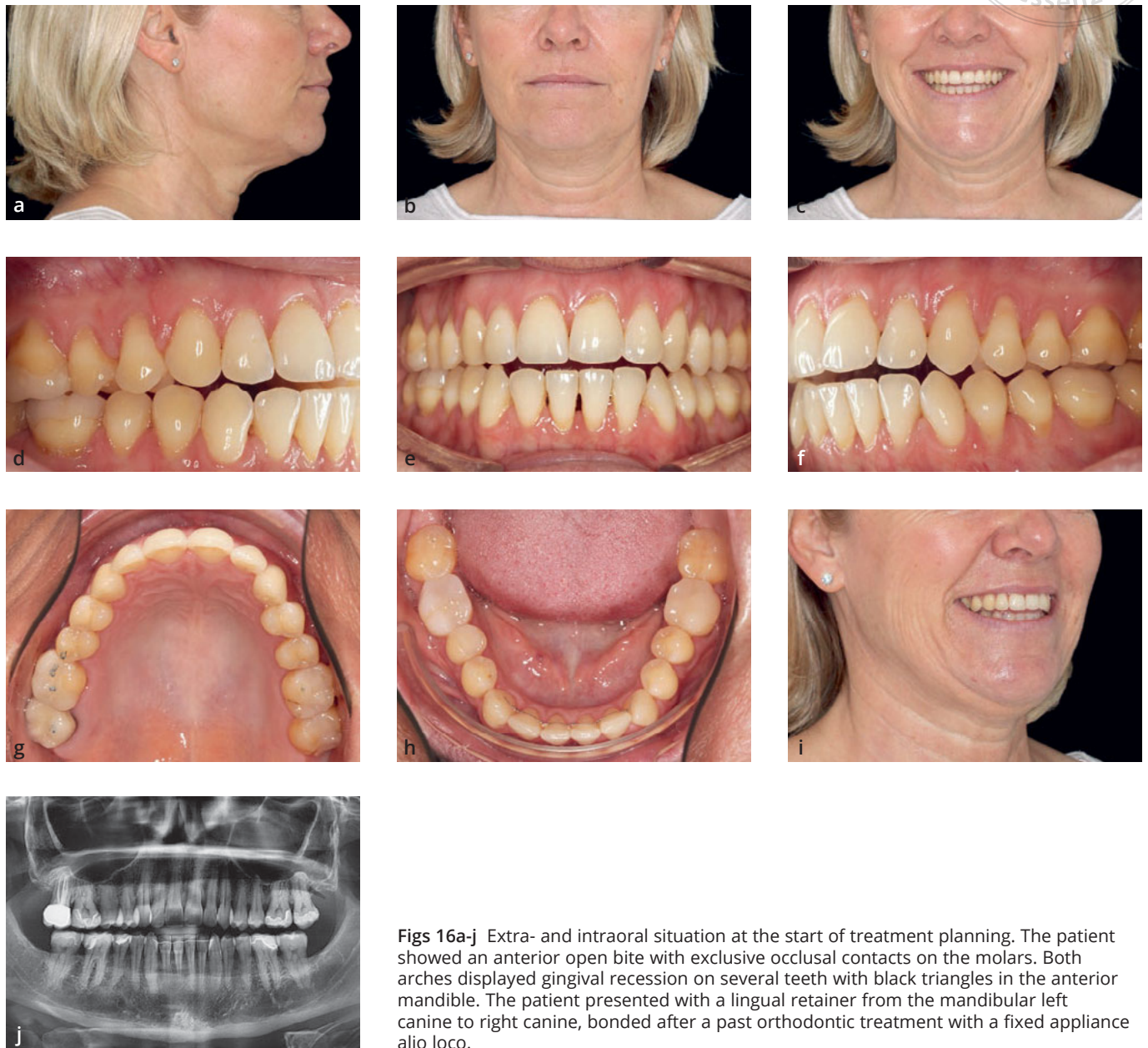### Patient 3: intrusion of posterior teeth and extrusion of anterior teeth with in-office aligners

The 55-year-old patient attended the present authors' office requiring orthodontic treatment due to an anterior open bite (Fig 16). She said that the bite had opened after the placement of new restorations on the maxillary and mandibular posterior teeth. The patient was wearing a lingual retainer from the mandibular left canine to right canine, bonded after a past orthodontic treatment with a fixed appliance alio loco. The panoramic radiograph showed the patient had received endodontic treatment in the past and had a conservatively preserved denture. Aligner treatment was planned for extrusion of the maxillary anterior teeth and intrusion of the posterior teeth to close the anterior open bite after the patient had received thorough myofunctional therapy. The patient changed dental practitioner and, in accordance with this, maximal occlusal reduction of the posterior restorations was planned to reduce the anterior open bite prior to orthodontic treatment.

Figure 17 shows the situation after occlusal reduction of the posterior restorations and removal of the mandibular lingual retainer and at the beginning of orthodontic treatment. A scan was taken (TRIOS 3, 3Shape, Copenhagen Denmark) and transferred into OnyxCeph Aligner 3D software (Image Instruments, Chemnitz, Germany) (Fig 18a). The virtual treatment plan included 14 stages, with two

aligners for each stage (0.50- and 0.65-mm CA Pro, Scheu Dental, Iserlohn, Germany). Horizontally positioned bevelled attachments were planned on the maxillary anterior teeth and canines as well as on the mandibular right central and lateral incisors to transmit optimal extrusive force, and vertical rectangular attachments were planned for anchorage on the mandibular canines. Up to 0.4 mm IPR was planned in both arches for alignment and to reduce black triangles. It was planned in accordance with the patient's wishes to maintain a slight midline deviation to avoid excessive IPR and a longer treatment time. The patient changed her aligners weekly and showed good compliance. After 7 months of treatment, the anterior open bite had already improved significantly (Fig 19). A new scan was taken for a final finishing phase and transferred into OnyxCeph Aligner 3D (Fig 20a). In this phase, minimal further extrusion of the anterior teeth and intrusion of the posterior teeth were again planned, with an additional six stages (Fig 20b).

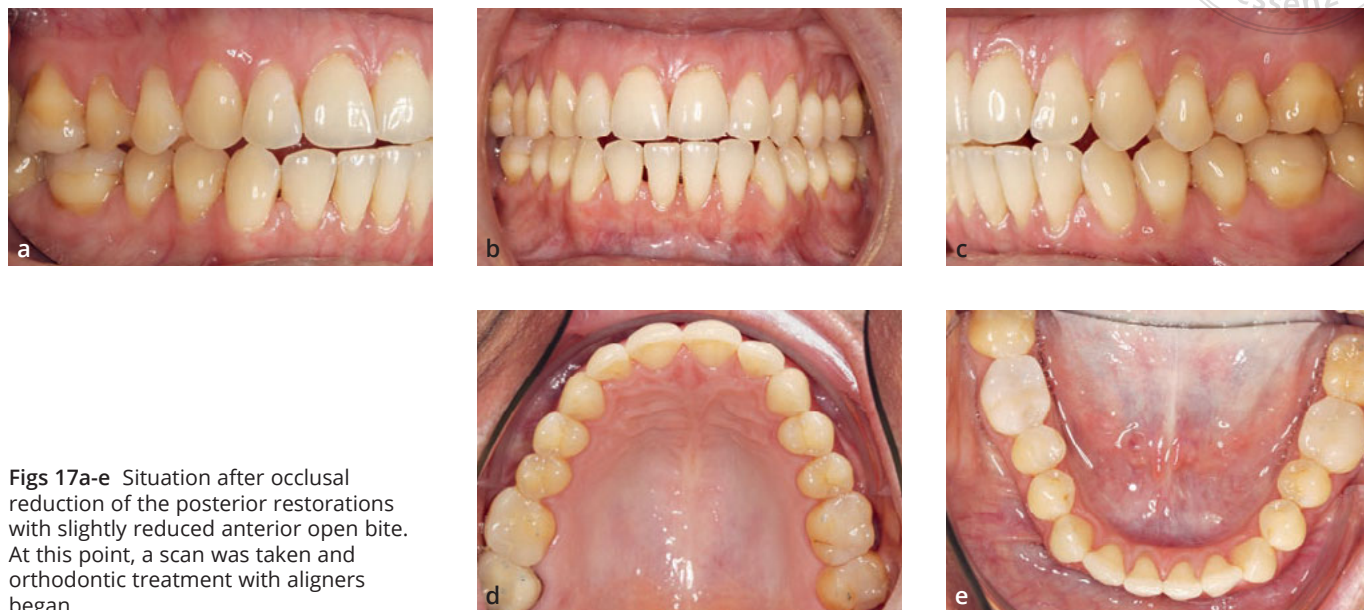After an overall treatment time of 40 weeks, the bite was completely closed (Fig 21). The resting position of the lip ("Emma" picture<sup>17</sup>) revealed harmonious incisor display of almost 2 mm. The black triangles in the anterior mandible had been reduced and the gingival recession showed a slight improvement, particularly in the maxillary premolar region. The panoramic radiograph revealed no pathologies.



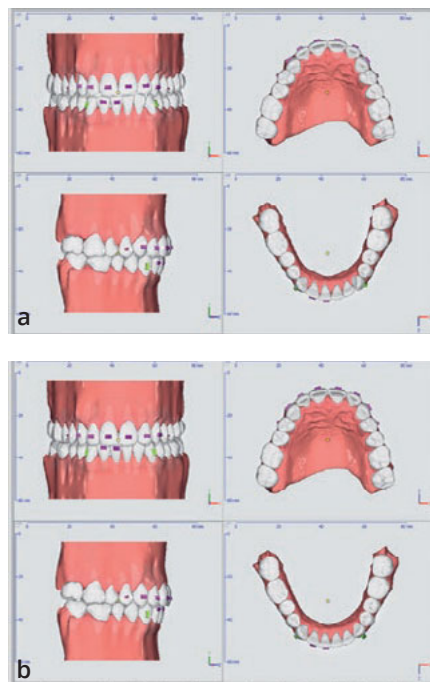
**Figs 16a-j** Extra- and intraoral situation at the start of treatment planning. The patient showed an anterior open bite with exclusive occlusal contacts on the molars. Both arches displayed gingival recession on several teeth with black triangles in the anterior mandible. The patient presented with a lingual retainer from the mandibular left canine to right canine, bonded after a past orthodontic treatment with a fixed appliance alio loco.

In accordance with the patient's wishes, the result was maintained with a lingual retainer in the mandible from the left first premolar to the right first premolar and a removable aligner in the maxilla. Figure 22 presents a comparison

of the situation before and after in-office aligner treatment with extrusion of the anterior teeth and intrusion of the posterior teeth.



**Figs 17a-e** Situation after occlusal reduction of the posterior restorations with slightly reduced anterior open bite. At this point, a scan was taken and orthodontic treatment with aligners began.



**Figs 18a-d** Transferral of the scan into OnyxCeph Aligner 3D software (Image Instruments, Chemnitz, Germany) and virtual treatment planning. The plan included 14 stages with two aligners each (0.50- and 0.65-mm CA Pro, Scheu Dental, Iserlohn, Germany). Horizontally positioned bevelled attachments were planned to be placed on the maxillary anterior teeth and canines as well as on the mandibular right central and lateral incisors, and vertical rectangular attachments were planned for anchorage on the mandibular canines. Up to 0.4 mm IPR was planned in both arches for alignment and to reduce black triangles. The tooth movement chart shows that molar intrusion was planned to be up to 1.06 mm and extrusion of the anterior teeth was planned to be up to 1.13 mm. \*According to FDI notation.

Maxilla														
Tooth*	17-16	16-15	15-14	14-13	13-12	12-11	11-21	21-22	22-23	23-24	24-25	25-26	26-27	Total
Amount of interproximal reduction (mm)	0.00 + 0.00	0.00 + 0.00	0.00 + 0.00	0.00 + 0.00	0.00 + 0.00	0.00 + 0.00	0.00 + 0.00	0.00 + 0.00	0.00 + 0.00	0.00 + 0.00	0.00 + 0.00	0.00 + 0.00	0.00 + 0.00	0.00
Total (mm)	0.00	0.00	0.00	0.00	0.00	0.00	0.00	0.00	0.00	0.00	0.00	0.00	0.00	0.00
Distance (mm)	0.02	0.07	0.00	-0.21	-0.19	-0.10	-0.13	-0.13	-0.11	-0.10	0.00	0.00	0.00	-0.87

Mandible														
Tooth*	47-46	46-45	45-44	44-43	43-42	42-41	41-31	31-32	32-33	33-34	34-35	35-36	36-37	Total
Amount of interproximal reduction (mm)	0.00 + 0.00	0.00 + 0.00	0.00 + 0.00	0.00 + 0.00	0.00 + 0.00	0.00 + 0.00	0.00 + 0.00	0.00 + 0.00	0.00 + 0.00	0.00 + 0.00	0.00 + 0.00	0.00 + 0.00	0.00 + 0.00	0.00
Total (mm)	0.00	0.00	0.00	0.00	0.00	0.00	0.00	0.00	0.00	0.00	0.00	0.00	0.00	0.00
Distance (mm)	0.00	0.02	0.04	-0.06	0.02	-0.44	-0.21	-0.22	-0.11	-0.23	-0.09	0.05	0.00	-1.22

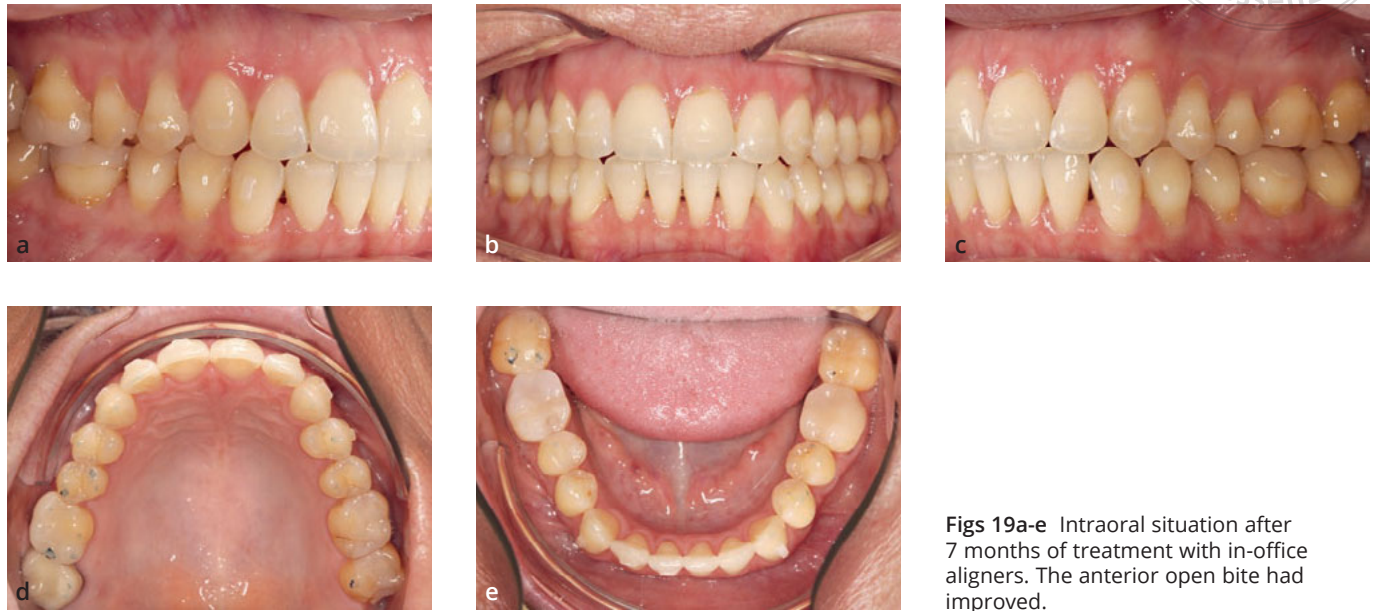
**c**

Maxilla																
Tooth*	18	17	16	15	14	13	12	11	21	22	23	24	25	26	27	28
Mesial interproximal reduction (mm)																
Distal interproximal reduction (mm)																
Inclination (degrees)		-2.60	-0.40	-7.60	-2.50	-2.10	-0.50	2.40	1.20	0.80	-7.40	-11.30	-2.50	-7.60	7.30	
Inclination +/- (degrees)						2.10	-3.00	-3.00	-3.20	-3.60	3.40					
Angulation (degrees)		2.50	-2.50	10.90	8.60	-1.40	0.10	-0.40	5.90	3.50	5.50	7.30	5.30	-3.10	-4.30	
Angulation +/- (degrees)						1.20	-1.00	-1.10	1.20	2.00	0.80					
Rotation +/- (degrees)			0.10			4.80	-3.10	-2.80	2.80	8.00	5.30	0.10	0.10	0.10	0.10	
Mesial +/- (mm)		-0.16	-0.11			-0.01	0.16		-0.11	-0.19	-0.10	-0.10	-0.10	-0.18	-0.28	
Vestibular +/- (mm)		-0.01	0.01			0.35	-0.14	-0.15	-0.67	-0.19	0.38	0.02		0.01	-0.05	
Occlusal +/- (mm)		-1.06	-0.40			0.64	0.79	0.79	1.12	1.13	0.42	-0.01	-0.01	-0.41	-0.06	

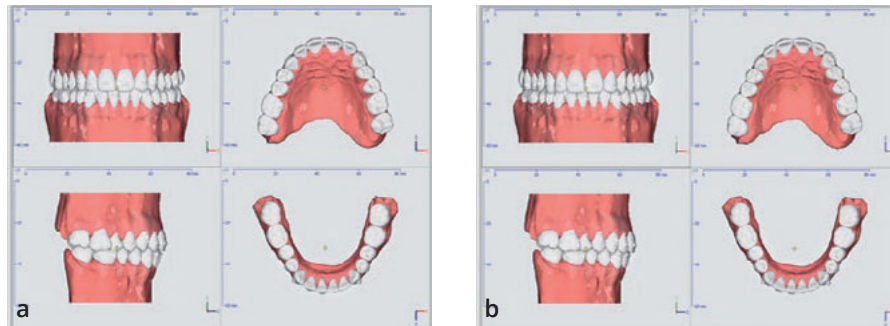
  

Mandible																
Tooth*	48	47	46	45	44	43	42	41	31	32	33	34	35	36	37	38
Amount of mesial interproximal reduction (mm)																
Amount of distal interproximal reduction (mm)																
Inclination (degrees)		-35.10	-32.20	-18.60	-14.90	-13.60	1.40	1.20	1.50	-0.60	-11.00	-18.30	-20.20	-37.80	-34.10	
Inclination +/- (degrees)							-4.90	-5.00	-2.10	-0.10	6.30					
Angulation (degrees)		-2.00	10.20	3.10	3.90	6.50	0.50	-1.30	0.50	1.30	10.90	5.00	2.50	-7.50	0.00	
Angulation +/- (degrees)									2.20	0.10	-0.60					
Rotation +/- (degrees)								0.90	4.10	-2.00	-33.50		-0.20			
Mesial +/- (mm)		-0.11	-0.08				-0.01	-0.29	0.45	0.56	0.19		0.19	-0.08	-0.06	
Vestibular +/- (mm)		0.01	-0.01	0.20	0.20		-0.39	-0.43	-0.31	0.13	0.11	0.50	0.46			
Occlusal +/- (mm)		-0.51	-0.25				0.42	0.34	0.19	0.03	0.82		-0.07	-0.25	-0.50	

**d**



**Figs 19a-e** Intraoral situation after 7 months of treatment with in-office aligners. The anterior open bite had improved.



**Figs 20a-c** Scan transferred into OnyxCeph Aligner 3D at the start of the second phase of treatment. Minimal further extrusion of anterior teeth and intrusion of posterior teeth were planned to improve the final position. IPR was minimal in both arches, up to 0.16 mm. \*According to FDI notation.

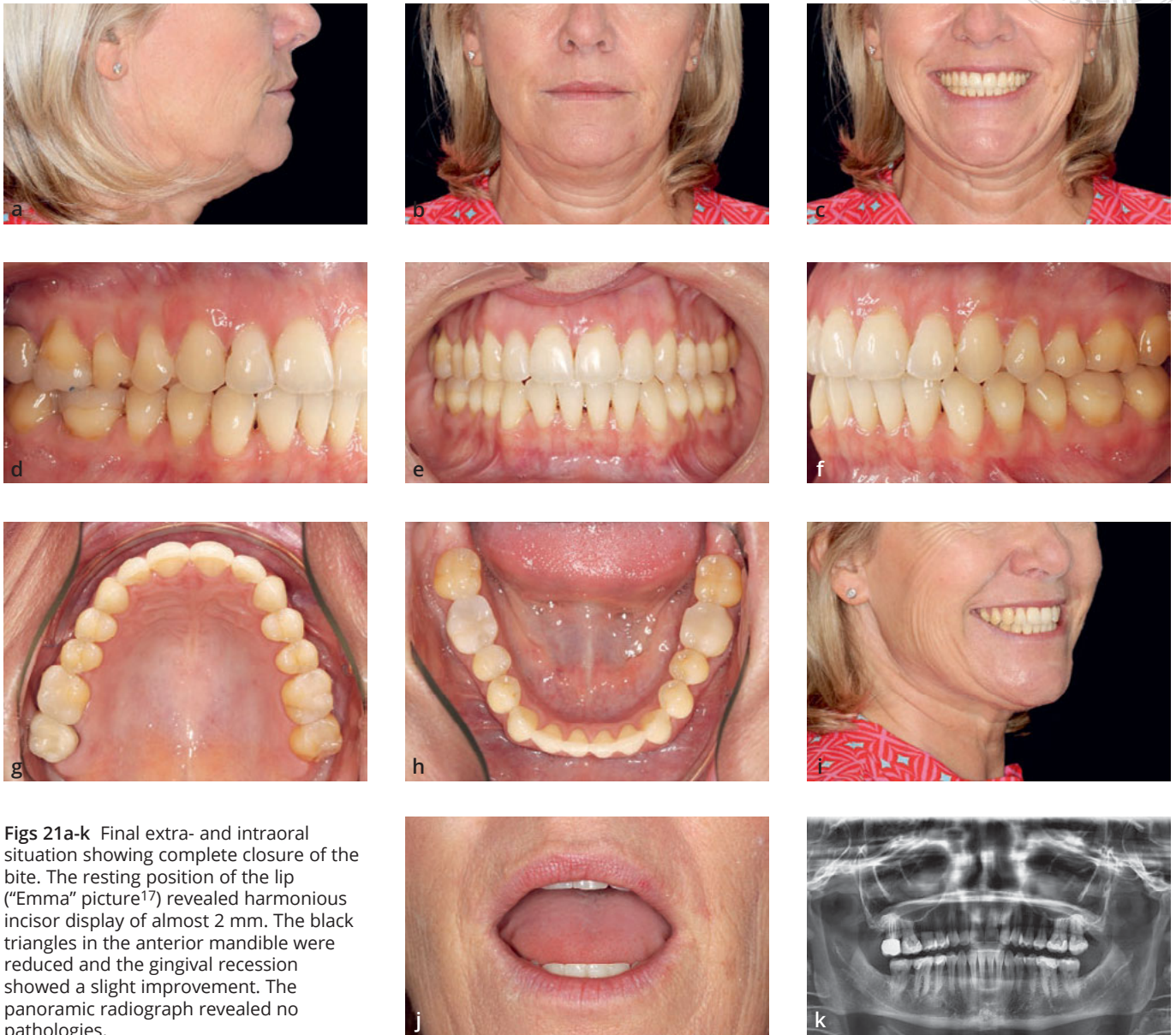Maxilla														
Tooth*	17-16	16-15	15-14	14-13	13-12	12-11	11-21	21-22	22-23	23-24	24-25	25-26	26-27	Total
Amount of interproximal reduction (mm)	0.00 +	0.00 +	0.00 +	0.00 +	0.00 +	0.00 +	0.00 +	0.00 +	0.00 +	0.00 +	0.00 +	0.00 +	0.00 +	
Total (mm)	0.00	0.00	0.00	0.00	0.00	0.00	0.00	0.00	0.00	0.00	0.00	0.00	0.00	0.00
Distance (mm)	0.00	-0.13	0.00	-0.13	-0.12	-0.04	0.02	-0.08	-0.10	-0.14	-0.04	0.00	0.00	-0.78

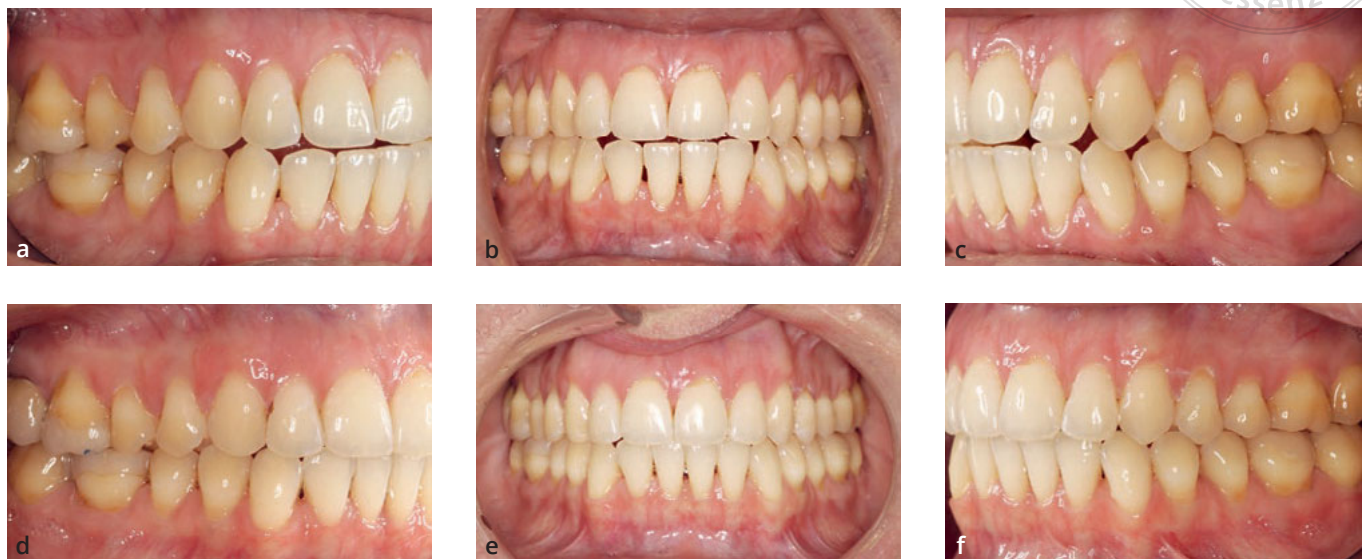Mandible														
Tooth*	47-46	46-45	45-44	44-43	43-42	42-41	41-31	31-32	32-33	33-34	34-35	35-36	36-37	Total
Amount of interproximal reduction (mm)	0.00 +	0.00 +	0.00 +	0.00 +	0.00 +	0.00 +	0.00 +	0.00 +	0.00 +	0.00 +	0.00 +	0.00 +	0.00 +	
Total (mm)	0.00	0.00	0.00	0.00	0.00	0.00	0.00	0.00	0.00	0.00	0.00	0.00	0.00	0.00
Distance (mm)	0.00	0.00	0.00	0.00	-0.11	-0.10	-0.15	-0.08	-0.16	0.00	0.00	0.02	0.00	-0.56

**c**





**Figs 21a-k** Final extra- and intraoral situation showing complete closure of the bite. The resting position of the lip (“Emma” picture<sup>17</sup>) revealed harmonious incisor display of almost 2 mm. The black triangles in the anterior mandible were reduced and the gingival recession showed a slight improvement. The panoramic radiograph revealed no pathologies.



**Figs 22a-f** Comparison of the situation before (a to c) and after (d to f) in-office aligner treatment with extrusion of the anterior teeth and intrusion of the posterior teeth.

### In-office open bite treatment with virtual articulators

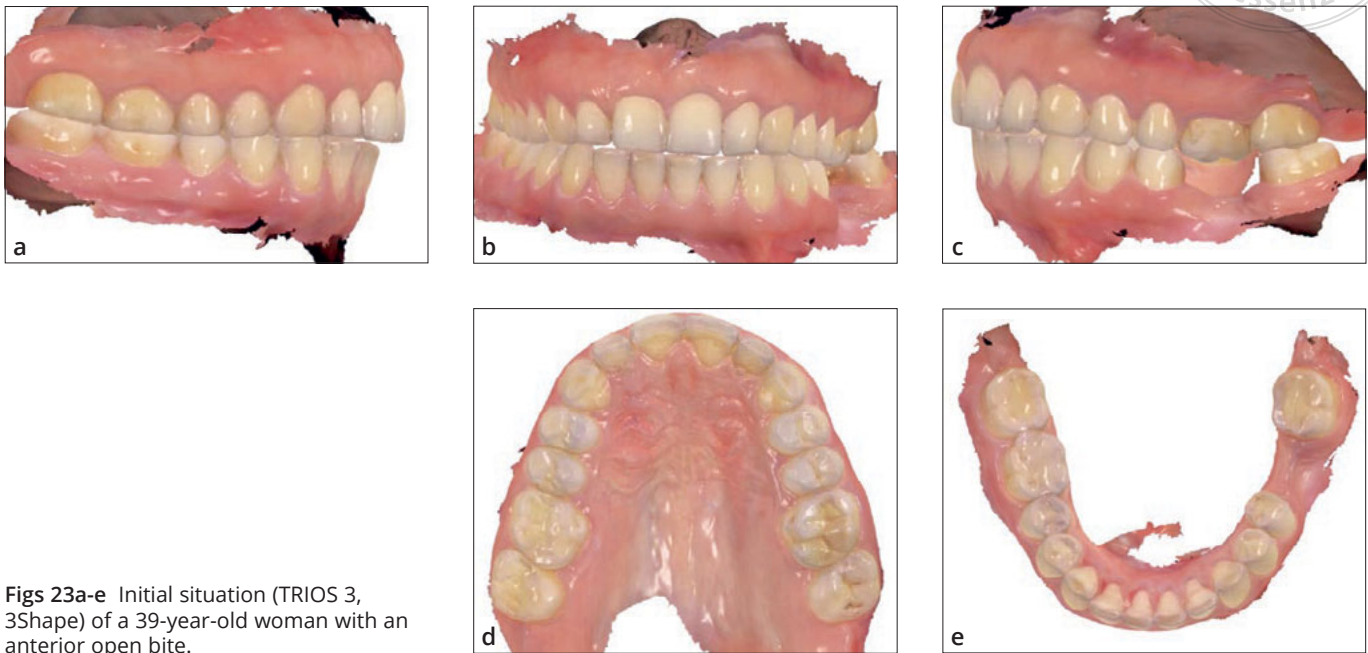

Digital recording of the condylar pathways in three dimensions, namely the sagittal, frontal and horizontal view, as well as visualisation of the joint spaces, have been aims in dentistry for many years<sup>24-31</sup> and can now finally be achieved in a reasonable amount of time and to a high degree of precision. It is now possible to visualise the temporomandibular joint (TMJ) exactly and magnified. Since August 2022, the present authors have been working with a virtual articulator, Dental Motion Decoder-System (DMD-System; Ignident, Ludwigshafen, Germany), in OnyxCeph Aligner 3D<sup>1</sup>.

DMD-System is a real-time 3D tracking system based on magnetic field technology. The movements of the mini-sensors, which are buccally bonded to the teeth with light-curing resin, are recorded and stored in real time in the magnetic field technology at a frequency recording speed of 66 Hz via two sensors, known as marker tools (3 g each). The mini-sensors are six degrees of freedom (6DOF) sensors that record the x-, y- and z-axis and the yaw axis simultaneously. The goal of digital motion analysis in orthodontics is to program a virtual articulator to create and optimise a functional occlusion. The axis can be recorded and transferred directly to OnyxCeph Aligner 3D. The exact pro-

cedure will be described in detail in a future article to be published in the Journal of Aligner Orthodontics. In the present study, the authors would like to discuss the advantage of using this procedure in the treatment of anterior open bite by rotating the mandible in the global centre of rotation individually for every patient to the maxilla after each virtual tooth movement. "Best fit" occlusion, as used with most software systems in the past, has thus become obsolete.

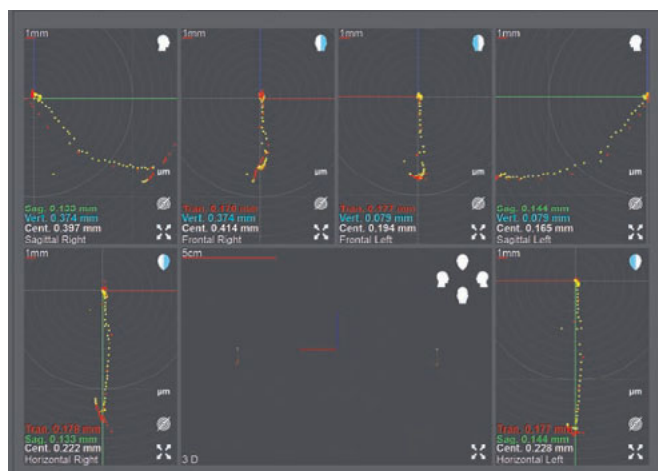
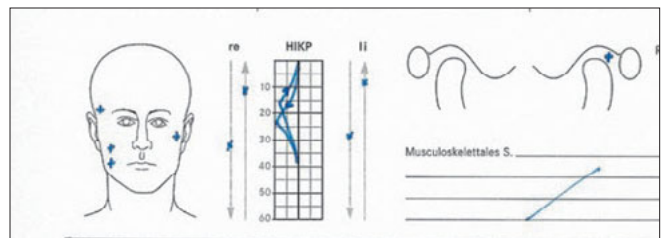
Figure 23 shows the initial situation of a 39-year-old woman with an open bite. The clinical functional examination showed a deviation with a terminal reciprocal anterior disc displacement. Palpation pain was observed in the left TMJ, right and left m. masseter, and right m. temporomandibularis anterior (Fig 24).

The trace during the protrusive movement (Fig 25) showed a jump in the opening and closing movement on the right side, and in the closing movement on the left. The right trace was relatively flat, whereas the left trace was still concave. In the opening movement (Fig 26), a jump on the right and left side could be observed at incursion and excursion. The allocation of the mandible to the maxilla (Figs 27a to c) was done in the corrected, physiological condylar position and matched exactly in this way, including the rotation

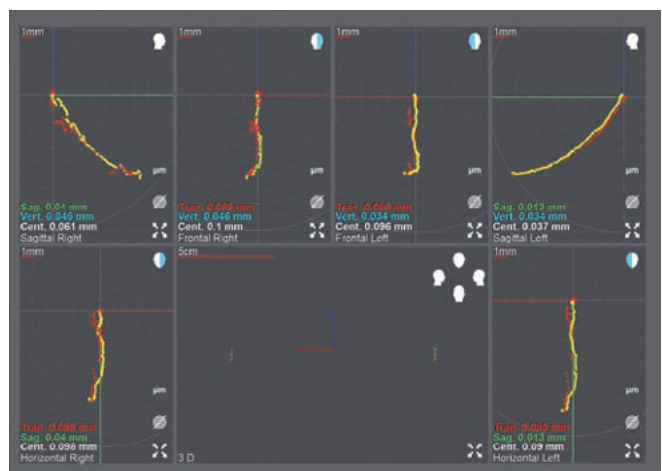


**Figs 23a-e** Initial situation (TRIOS 3, 3Shape) of a 39-year-old woman with an anterior open bite.

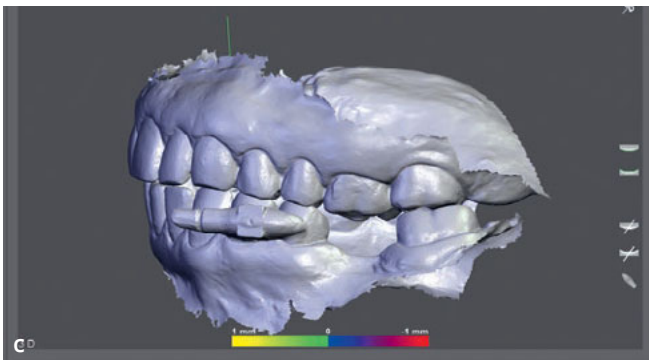
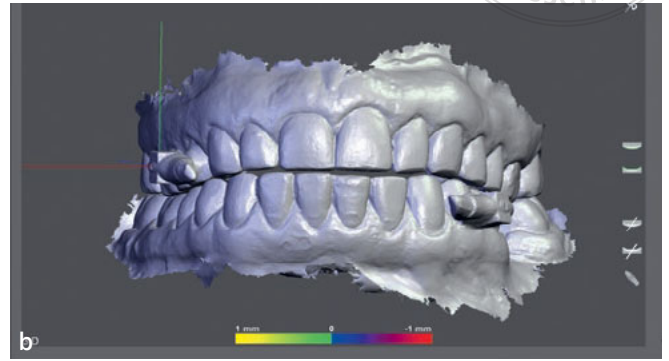
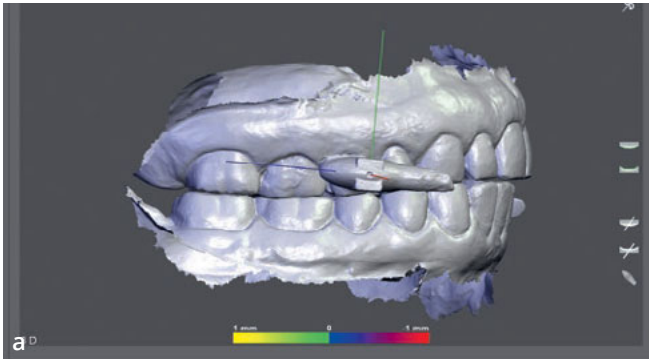
**Fig 24** The clinical functional examination showed a deviation with a terminal reciprocal anterior disc displacement. Palpation pain was observed in the left TMJ, right and left m. masseter, and right m. temporomandibularis anterior.



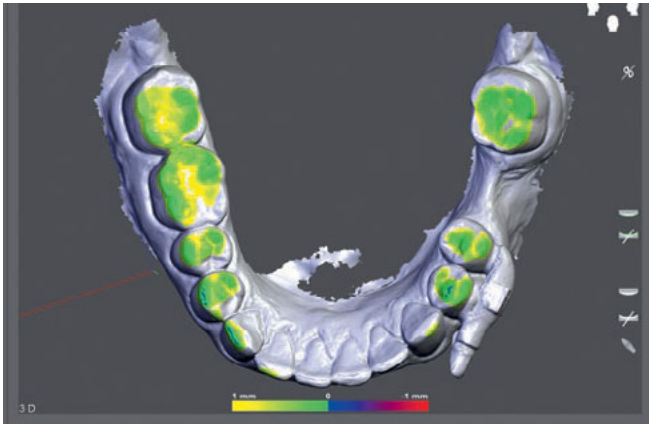
**Fig 25** The trace of the protrusion movement in the DMD-System showed a jump in the opening (yellow) and closing movement (red) on the right side, and in the closing movement (red) on the left. The right trace was relatively flat, whereas the left trace was still concave.



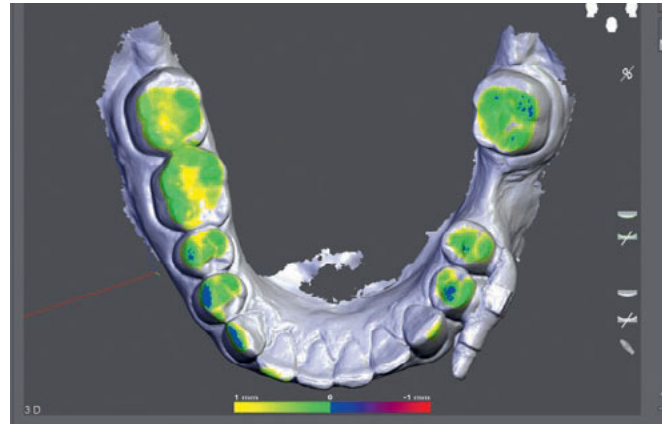
**Fig 26** In the opening movement with cranial compression, a jump on the left and right side could be observed at incursion (yellow) and excursion (red).



**Figs 27a-c** Assignment of the mandible to the maxilla in the corrected, physiological condylar position for transfer into OnyxCeph Aligner 3D software for VTS\_Closed Jaw.



**Fig 28** In this assignment (DMD-System VTS\_Closed Jaw), the first contacts, which were transferred exactly into OnyxCeph Aligner 3D, were on the mandibular left first premolar and right canine and first premolar (contact points in dark blue). The virtual tooth movement took place from this position.

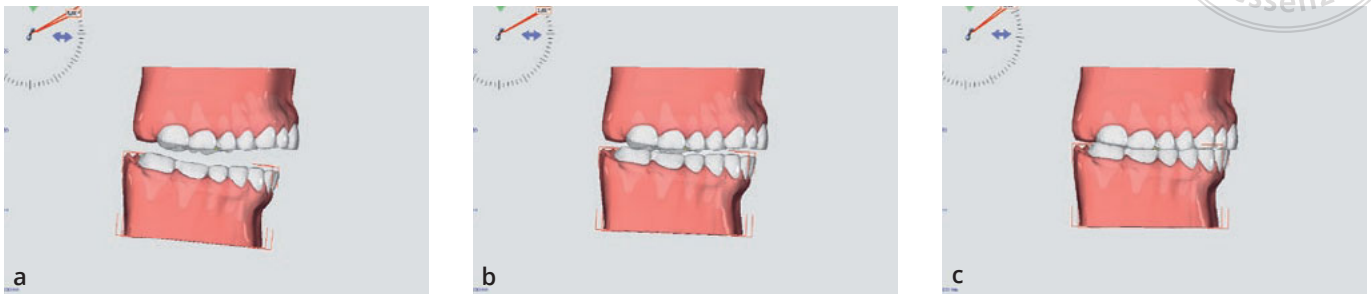


**Fig 29** Upon closing further from the Closed Jaw\_First contact in DMD-System, the next contacts on the mandibular left second premolar and second molar and right second premolar could be observed (blue).

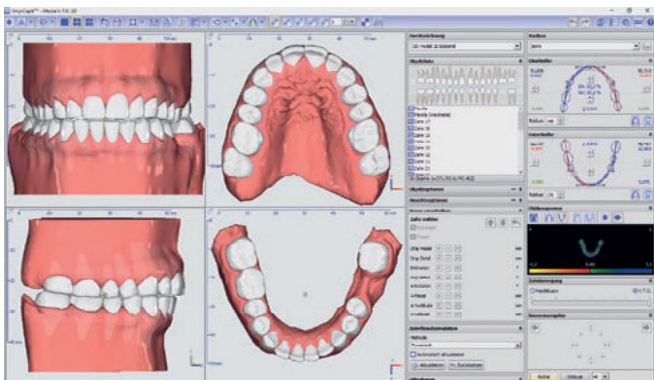
axis in the global centre of rotation in OnyxCeph Aligner 3D. In this assignment (Fig 28), the first contacts, which were transferred exactly into OnyxCeph Aligner 3D software, were on the mandibular left first premolar and right canine and first premolar. The virtual tooth movement took place from this position. Upon closing further in DMD-System, the

next contacts on the mandibular left second premolar and second molar and right second premolar could be observed (Fig 29).

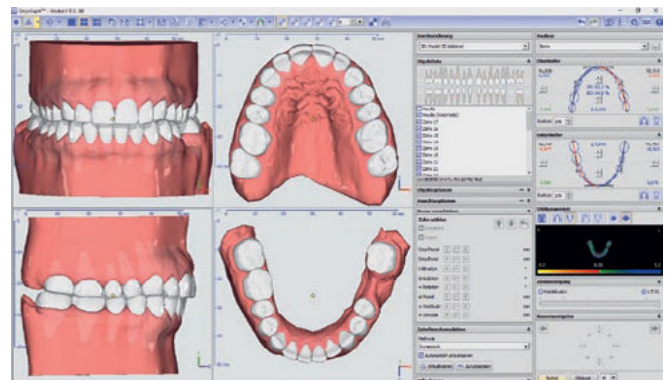
Figure 30 shows the axis of rotation in the global centre of rotation, and arch closure to centric occlusion on the mandibular left first premolar and right canine and first



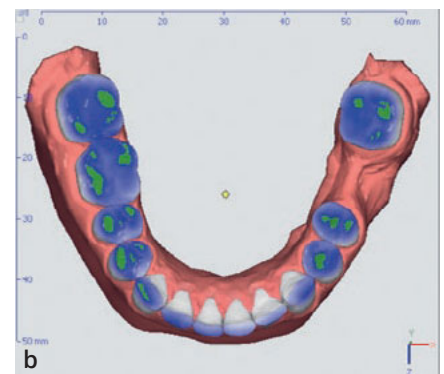
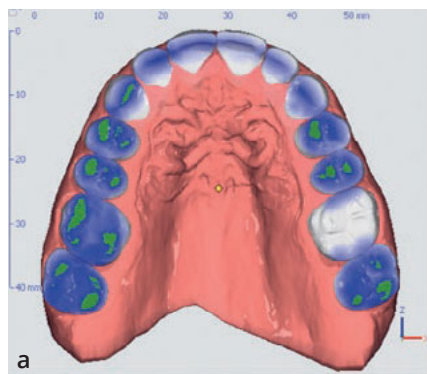
**Fig 30a-c** (a) Axis of rotation in the global centre of rotation, arch in OnyxCeph Aligner 3D, Axis 1. (b) Axis of rotation in the global centre of rotation, arch in OnyxCeph Aligner 3D, Axis 2. (c) Axis of rotation in the global centre of rotation, arch in OnyxCeph Aligner 3D in occlusal contact with the mandibular first premolars and right canine, Axis 3.



**Fig 31** Initial situation transferred into OnyxCeph Aligner 3D.



**Fig 32** Planned situation in OnyxCeph Aligner 3D after intrusion of the mandibular left first premolar and right canine and first premolar, extrusion of the maxillary right and left lateral and central incisors and closure of the anterior open bite.



**Figs 33a-b** Final planned occlusion with an equal occlusal contact pattern.

premolar in OnyxCeph Aligner 3D. Figure 31 demonstrates the virtual treatment simulation in the initial situation, Figure 32 shows the final occlusion after intrusion of the mandibular first premolars and right canine and additional extrusion of the maxillary central and lateral incisors, and Fig 33 the final occlusion.

## Summary

Aligner treatment, whether outsourced or in-office, has become a valuable alternative to fixed appliance techniques. Open bite treatment in particular seems to be highly predictable with correct virtual treatment planning and an-



chorage due to attachments. The use of virtual articulators enables even greater precision in diagnostics and treatment planning. Although treatment for severe cases of open bite in adults might require surgery or at least skeletal anchorage with TADs, moderate open bites can be treated with anterior extrusion, posterior intrusion or combinations of these with aligner orthodontics alone. The use of aligners in open bite treatment offers a highly predictable, comfortable and aesthetic alternative for patients that causes fewer side effects than fixed appliance techniques.

## Declaration

The authors declare there are no conflicts of interest relating to this study.

## References

- Schupp W, Haubrich J (eds). *Aligner Orthodontics and Orofacial Orthopedics*. Berlin: Quintessence Publishing; 2023.
- Larsson E. Artificial sucking habits: Etiology, prevalence and effect on occlusion. *Int J Orofacial Myology* 1994;20:10–21.
- Fraser C. Tongue thrust and its influence in orthodontics. *Int J Orthod Milwaukee* 2006;17:9–18.
- Ngan P, Fields HW. Open bite: A review of etiology and management. *Pediatr Dent* 1997;19:91–98.
- Kasparaviciene K, Sidlauskas A, Zasciurinskiene E, et al. The prevalence of malocclusion and oral habits among 5-7-year-old children. *Med Sci Monit* 2014;20:2036–2042.
- Cenzato N, Iannotti L, Maspero C. Open bite and atypical swallowing: Orthodontic treatment, speech therapy or both? A literature review. *Eur J Paediatr Dent* 2021;22:286–290.
- Schupp W, Haubrich J, Neumann I. Treatment of anterior open bite with the Invisalign system. *J Clin Orthod* 2010;44:501–507.
- Giancotti A, Garino F, Mampieri G. Use of clear aligners in open bite cases: An unexpected treatment option. *J Orthod* 2017;44:114–125.
- Pokorná M, Marek I, Kučera J, Tycová H, Tvardek J. Cephalometric changes following clear aligner treatment in patients with anterior open bite. *J Aligner Orthod* 2022;6:93–102.
- Moshiri S, Araujo EA, McCray JF, Thiesen G, Kim KB. Cephalometric evaluation of adult anterior open bite non-extraction treatment with Invisalign. *Dental Press J Orthod* 2017;22:30–38.
- Sayahpour B, Majdani A, Eslami S, Buehling S, Goteni M, Kopp S. Treatment of anterior open bite with the Invisalign First system: A case report. *J Aligner Orthod* 2022;6:189–197.
- Dayan W, Aliaga-Del Castillo A, Janson G. Open-bite treatment with aligners and selective posterior intrusion. *J Clin Orthod* 2019;53:53–54.
- Giancotti A, Germano F, Muzzi F, Greco M. A miniscrew-supported intrusion auxiliary for open-bite treatment with Invisalign. *J Clin Orthod* 2014;48:348–358.
- Park HS, Kwon TG, Kwon OW. Treatment of open bite with micro screw implant anchorage. *Am J Orthod Dentofacial Orthop* 2004;126:627–636.
- Ojima K, Dan C, Watanabe H, Kumagai Y, Nanda R. The biomechanics of aligner orthodontics in open-bite cases. *J Clin Orthod* 2019;53:699–712.
- Greco M, Rossini G, Rombola A. Simplifying the approach of open bite treatment with aligners and selective micro-osteoperforations: An adult case report. *Int Orthod* 2021;19:159–169.
- Zachrisson BU. Facial esthetics: Guide to tooth positioning and maxillary incisor display. *World J Orthod* 2007;8:308–314.
- Vela-Hernandez A, Lopez-Garcia R, Garcia-Sanz V, Paredes-Gallardo V, Lasagabaster-Latorre F. Nonsurgical treatment of skeletal anterior open bite in adult patients: Posterior build-ups. *Angle Orthod* 2017;87:33–40.
- Erbe C, Crismani A. Interview with Univ.-Prof. D. Christina Erbe, Director of the Department of Orthodontics, University Medical Center Mainz. *Inf Orthod Kieferorthop* 2022;54:205–207.
- Arat M, Iseri H. Orthodontic and orthopaedic approach in the treatment of skeletal open bite. *Eur J Orthod* 1992;14:207–215.
- Ryan MJ, Schneider BJ, BeGole EA, Muhl ZF. Opening rotations of the mandible during and after treatment. *Am J Orthod Dentofacial Orthop* 1998;114:142–149.
- Schupp W, Haubrich J, Ojima K, Dan C, Kumagai Y, Otsuka S. Accelerated Invisalign treatment of patients with a skeletal Class III. *J Aligner Orthod* 2017;1:37–57.
- Ojima K. A novel approach for aligner orthodontics: Biomechanics-oriented orthodontics with Tads. *J Aligner Orthod* 2019;3:303–311.
- Gartner C, Kordass B. The virtual articulator: Development and evaluation. *Int J Comput Dent* 2003;6:11–24.
- Bisler A, Bockholt U, Kordass B, Suchan M, Voss G. The virtual articulator. *Int J Comput Dent* 2002;5:101–106.
- Kordass B, Gartner C, Sohnel A, et al. The virtual articulator in dentistry: Concept and development. *Dent Clin North Am* 2002;46:493–506.
- Maestre-Ferrín L, Romero-Millán J, Peñarrocha-Oltra D, Peñarrocha-Diago M. Virtual articulator for the analysis of dental occlusion: An update. *Med Oral Patol Oral Cir Bucal* 2012;17:e160–e163.
- Park JH, Lee KM, Kim JC, Moon DN, Lee GH. Evaluation of mandibular position for splint therapy using a virtual articulator. *J Clin Orthod* 2020;54:466–472.
- Buduru S, Finta E, Almasan O, et al. Clinical occlusion analysis versus semi-adjustable articulator and virtual articulator occlusion analysis. *Med Pharm Rep* 2020;93:292–296.
- Li L, Sun Y, Wang Y, et al. Accuracy of a novel virtual articulator for recording three-dimensional dentition. *Int J Prosthodont* 2020;33:441–451.
- Park JH, Lee GH, Moon DN, Kim JC, Park M, Lee KM. A digital approach to the evaluation of mandibular position by using a virtual articulator. *J Prosthet Dent* 2021;125:849–853.